



# CLINICAL UPDATE

CURRENT TRENDS IN THE PRACTICE OF MEDICINE

**SPECIAL EDITION**

Focus on  
Endocrinology

## Endoscopic Transnasal Surgery for Pituitary Tumors

Since the 1970s, the standard surgical approach for resection of most pituitary tumors has been transsphenoidal. In the mid 1990s, Mayo Clinic surgeons began using the nasal endoscope in a modification of the standard surgical technique. This new endoscopic transnasal technique decreases operative time, length of hospitalization, and patient discomfort, without compromising surgical success.

### Sublabial Transseptal Approach

This technique, which had been the standard procedure for resection of pituitary tumors at Mayo Clinic since the 1970s, involves making a sublabial incision for access to the nasal cavity and then removing the nasal septum (Figure 1). The sphenoid sinus is entered, allowing access to the sella turcica. After resection of the tumor, the nasal septum is replaced, requiring nasal packing postoperatively.

### Endoscopic Transnasal Approach

This technique requires no external incision. The nasal endoscope is advanced through a nostril to the anterior wall of the sphenoid sinus (Figure 2). The sphenoid ostium is enlarged, and the posterior portion of the vomer is

### Points to Remember

- A new approach for transsphenoidal resection of pituitary tumors, using the nasal endoscope, was introduced in the 1990s.
- Endoscopic transnasal resection is now the standard surgical procedure for treatment of pituitary tumors at Mayo Clinic.
- Surgical success equals that of the previously used sublabial transseptal approach.
- Operative time, anesthesia time, hospital length of stay, and patient discomfort are less compared with the sublabial transseptal approach.

### Inside This Issue

**Primary Aldosteronism: The Role of Adrenal Venous Sampling** . . . . . 3

**Laparoscopic Adrenalectomy** . . . . . 5

**Graves' Ophthalmopathy: Medical vs Surgical Treatment of Severe Disease** . . . . . 6

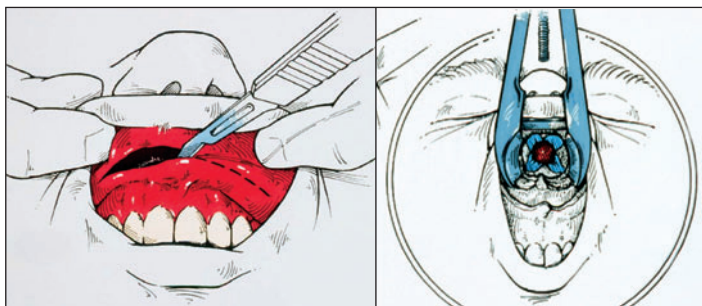


Figure 1. The sublabial transseptal surgical approach. A sublabial incision is made for access to the nasal cavity (left panel) for removal of the nasal septum. The sella turcica is accessed through the sphenoid sinus (right panel).

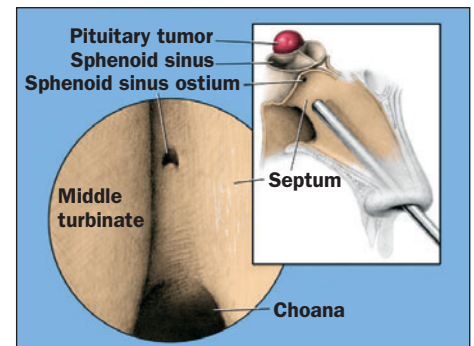


Figure 2. The endoscopic transnasal approach. The nasal endoscope is placed through a nostril and advanced to the anterior wall of the sphenoid sinus. The sphenoid ostium is identified and enlarged for removal of the posterior portion of the vomer, thus allowing access to the sphenoid sinus.

<b>Endoscopic</b>	<b>Sublabial</b>
No external incision	Sublabial incision
Nasal septum intact	Nasal septum removed and replaced
No postop nasal packing	Postop nasal packing for 3-5 days
Operating microscope	Operating microscope
Smaller operating field	Larger operating field
Field 10° off center	Field at 90°
Endoscopic visualization	—

removed, allowing access to the sphenoid sinus. After placement of a self-retaining nasal speculum, the sella turcica is entered, and the neurosurgical portion of the procedure is undertaken as with the sublabial transseptal approach. After resection of the tumor, the nasal speculum is withdrawn, the nasal septum is adjusted to midline if necessary, and a mustache nasal dressing is applied.

**Endoscopic Transnasal vs Sublabial Transseptal Approach**

The similarities and differences between the 2 techniques are summarized in the table. The

main difference from the surgeon’s standpoint is that with the endoscopic transnasal approach the surgical field is smaller and is angled approximately 10° off center (Figure 3). The disadvantages this presents to the surgeon can be overcome with experience. For the patient, the absence of the sublabial incision eliminates the possibility of postoperative lip numbness. Also, leaving the nasal septum intact decreases postoperative discomfort from nasal packs and reduces the chance of complications related to manipulation of the nasal septum.

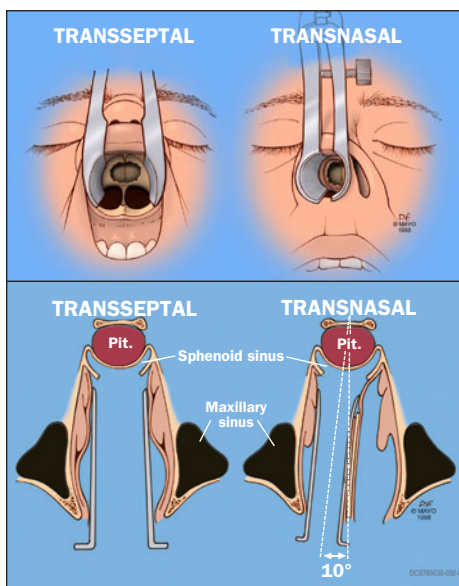
A retrospective case-controlled analysis of the initial experience at Mayo Clinic with the endoscopic

transnasal technique for resection of nonfunctioning pituitary macroadenomas was published in 1999. This study compared operative outcomes in patients who had undergone the standard sublabial transseptal procedure with the outcomes in patients who had the endoscopic procedure during the first 3 years after the procedure was introduced. The results showed no differences in completeness of tumor resection, change in visual field defects, or alterations in pituitary function between the 2 groups. The operative time, anesthesia time, and hospital length of stay were less in the endoscopic transnasal group (Figure 4).

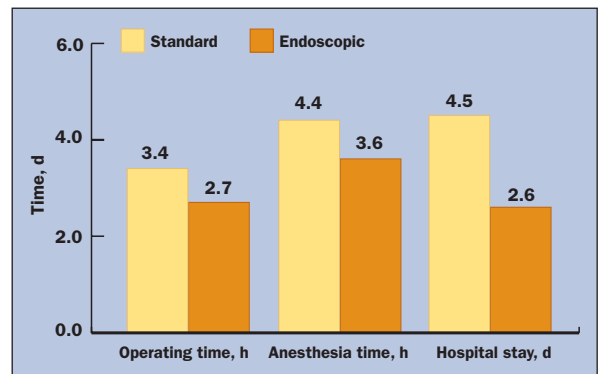
**Perioperative Management**

The endoscopic transnasal approach has now become the standard procedure to remove functioning and nonfunctioning pituitary adenomas and other sellar masses. Currently, Mayo Clinic neurosurgeons perform approximately 120 transsphenoidal procedures annually. Patients without medical or surgical complications (about 90%) are typically dismissed the morning after surgery and are seen as outpatients by the endocrinologist that afternoon. Any immediate postoperative hormonal deficiencies are treated, and a plan to assess for late postoperative hormonal and surgical complications is developed.

If you have questions about the treatment of pituitary tumors or if you have a patient you think might benefit from consultation with an endocrinologist and a neurosurgeon at Mayo Clinic, a facilitated appointment can be made by calling 800-313-5077.



**Figure 3.** The surgical field for endoscopic transnasal surgery is smaller than that for the endoscopic transnasal approach and is angled approximately 10° off center.



**Figure 4.** Procedure duration, anesthesia time, and length of hospital stay in patients undergoing standard sublabial transseptal surgery compared with those having endoscopic transnasal surgery. The differences were statistically significant (P<.001).

## Primary Aldosteronism: The Role of Adrenal Venous Sampling

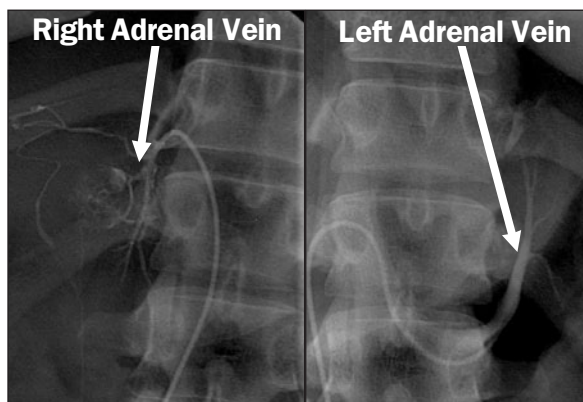
The triad of hypertension, hypokalemia, and an aldosterone-producing adenoma (APA) of the adrenal gland was first reported by Conn in 1955. The hypertension and hypokalemia in Conn's first patient were cured by removal of an adrenal adenoma. However, over the past 50 years, it has become clear that:

- Primary aldosteronism (PA) is more common than previously thought.
- PA has more than 1 cause, and most patients with PA have bilateral idiopathic hyperaldosteronism (IHA).
- IHA patients should be treated with an aldosterone-receptor antagonist.

Distinguishing the subtype of PA is critical in assessing treatment options. Unilateral adrenalectomy in patients with APA results in normalization of hypokalemia in all patients and normalization of blood pressure in at least a third of these operated patients and mitigates hypertension in nearly all. In patients with IHA, unilateral or bilateral adrenalectomy seldom corrects hypertension. Thus, it is essential to differentiate APA from IHA.

In 1967, selective adrenal venous sampling (AVS) for aldosterone was first proposed as a test to distinguish between APA and IHA. However, it is an invasive and difficult technique because both adrenal veins must be sampled for meaningful comparison (Figure 1).

When full-body CT became available in the late 1970s, it was thought to be a good test to distinguish among the subtypes of PA. However,



**Figure 1.** Radiographs show catheters placed in the right and left adrenal veins.

### Points to Remember

- **Primary aldosteronism may be the most common form of secondary hypertension in non-nicotine-dependent patients.**
- **CT accurately distinguishes unilateral from bilateral adrenal disease in only 53% of patients with primary aldosteronism.**
- **A unilateral source of aldosterone excess may be found even in patients who have normal-appearing or thickened limbs of the adrenal glands on CT.**
- **Adrenal venous sampling for aldosterone is very accurate (~95% sensitivity, 100% specificity) in identifying unilateral adrenal disease as the cause of primary aldosteronism.**
- **If surgery is considered as a treatment option for a patient with primary aldosteronism, adrenal venous sampling is an essential diagnostic step.**

because of the prevalence of nonfunctioning cortical adenomas, hormonal hyperfunction cannot be inferred simply from the presence of a nodule. A small APA may be labeled incorrectly as an IHA on the basis of CT findings of bilateral nodularity or normal-appearing adrenals. Adrenal incidentalomas are uncommon in young patients; in this case, when a solitary unilateral macronodule (>1 cm) and a normal contralateral adrenal are found on CT, unilateral adrenalectomy is reasonable to consider. However, in many cases, CT may demonstrate normal-appearing adrenals, minimal unilateral adrenal-limb thickening, unilateral micronodules ( $\leq 1$  cm), or bilateral macronodules. An approach to these clinical dilemmas is shown in the algorithm (see Figure 2 on page 4). Using this approach, AVS is performed in approximately 20% of Mayo Clinic patients with PA.

Patients with APAs have more severe hypertension, more frequent hypokalemia, and

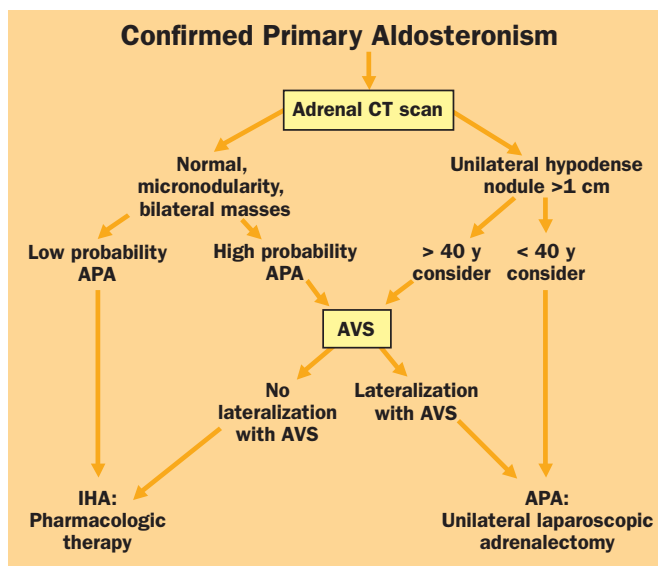


higher plasma (>25 ng/dL) and urinary (>30 µg/24 h) levels of aldosterone and are younger than those with IHA. Patients with these findings are considered to have a “high probability” of APA. However, these findings are not absolute predictors of unilateral vs bilateral adrenal disease.

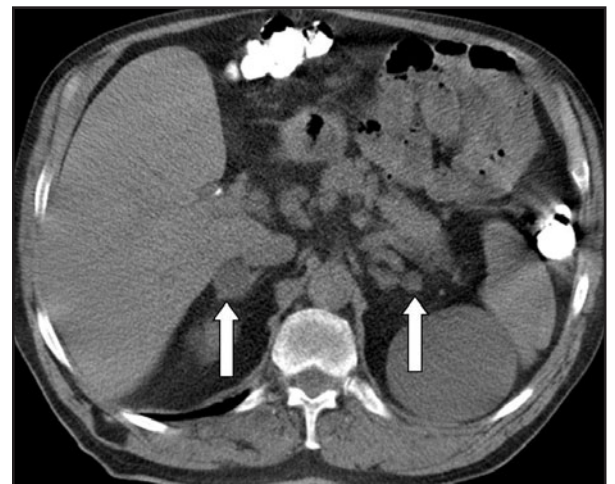
Between September 1990 and October 2003, at Mayo Clinic in Rochester, 203 PA patients (mean age, 53 years; range, 17-80 years; 163 men) were selected prospectively for AVS on the basis of degree of aldosterone excess, age, desire for surgical treatment, and CT findings. Both adrenal veins were catheterized in 194 (96%). The 110 patients (57%) with unilateral aldosterone hypersecretion included 24 of 58 patients (41%) with normal adrenal CT findings, 24 of 47 (51%) with unilateral micronodule (≤10 mm) apparent on

CT (7 had unilateral aldosterone hypersecretion from the contralateral adrenal), 21 of 32 (66%) with unilateral macronodule (>10 mm) apparent on CT (1 had unilateral aldosterone hypersecretion from the contralateral adrenal), 16 of 33 (48%) with bilateral micronodules, and 2 of 6 (33%) with bilateral macronodules. On the basis of CT findings alone, 42 patients (22%) would have been incorrectly excluded as candidates for adrenalectomy, and 48 (25%) might have had unnecessary or inappropriate adrenalectomy. Therefore, AVS is an essential diagnostic step in most patients for whom surgery is being considered to distinguish between unilateral and bilateral adrenal aldosterone hypersecretion (Figure 3).

If you have questions about AVS or if you have a patient you think may benefit from AVS, a facilitated appointment at Mayo Clinic can be made by calling 800-313-5077.



**Figure 2.** Algorithm shows an approach to the subtype evaluation of the patient with primary aldosteronism. APA, aldosterone-producing adenoma; AVS, adrenal venous sampling; IHA, idiopathic hyperaldosteronism.



**Figure 3.** Adrenal CT shows a 21-mm right adrenal nodule (left arrow) and an 11-mm left adrenal nodule (right arrow). Adrenal venous sampling lateralized aldosterone secretion to the left (the smaller adrenal abnormality on CT), a left aldosterone-producing adenoma was removed, and the patient's hypertension was cured.

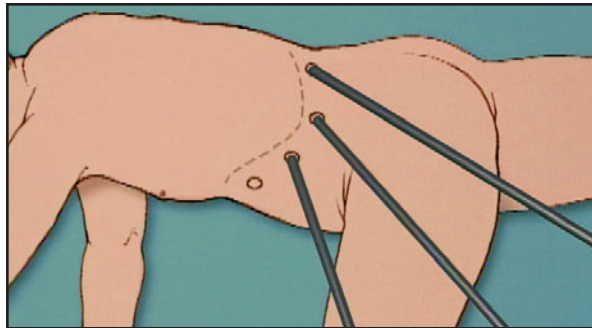
## Laparoscopic Adrenalectomy

For many years, open posterior adrenalectomy with resection of the 12th rib was the most common and accepted surgical approach for many functioning and nonfunctioning, benign, primary adrenal neoplasms. This operative approach had clear-cut advantages over standard laparotomy in terms of reduced pulmonary complications, more rapid return of gastrointestinal tract function, less blood loss,

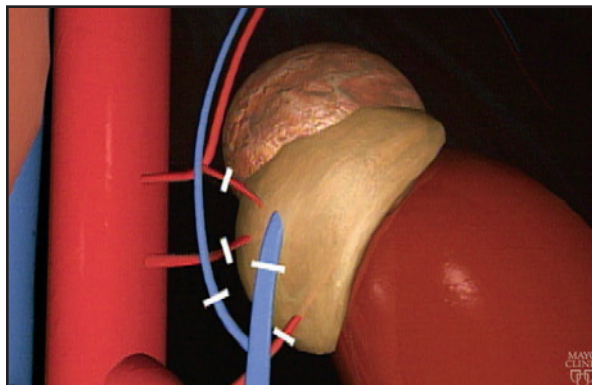
and more rapid recovery. However, with long-term follow-up, it became apparent that more than half the patients undergoing posterior adrenalectomy had some degree of long-term incision-related morbidity, including flank pain, paresthesias, and loss of muscle tone characterized by a bulging flank caused by subcostal nerve injury. With the advent of minimally invasive surgery, the transperitoneal

approach to laparoscopic adrenalectomy was developed to manage both functioning and nonfunctioning adrenal neoplasms (Figures 1 and 2). This innovation stimulated worldwide interest, resulting in a procedure that has become the standard for most functioning and nonfunctioning (benign) adrenal neoplasms smaller than 8 cm.

Between 1992 and 2002, Mayo Clinic endocrine surgeons performed 336 laparoscopic adrenalectomies in 290 patients. Ninety-one percent were completed laparoscopically (47% men, 53% women). Forty-two percent of the adrenalectomies were right-sided, 42% left-sided, and 16% bilateral. Functioning adrenal tumors comprised 84% of this operative experience (primary aldosteronism, 34%; Cushing's syndrome,



**Figure 1.** The lateral transabdominal approach to laparoscopic adrenalectomy. The lateral decubitus position of the patient and the medial rotation of the viscera allow gravity to keep the liver, bowel, and spleen away from the surgical field. The skin incisions are 1 cm in length and 2 cm below and parallel to the costal margin. Four 10-mm trocar ports are established, the laparoscope is placed through the most anterior trocar, and the working instruments are placed through the other ports.



**Figure 2.** The main adrenal vein is identified, clipped, and transected. The remaining adrenal vessels are also clipped and transected. The adrenal gland and tumor are resected and placed in a retrieval pouch and pulled up through the port site.

### Points to Remember

- **Laparoscopic adrenalectomy is the surgical approach of choice for most benign functioning and nonfunctioning adrenal disorders that require resection.**
- **In the Mayo Clinic laparoscopic adrenalectomy experience, the mean hospital stay was 3 days, and the mean time to return to normal activities was 4 to 6 days.**
- **Obvious adrenocortical carcinomas are still best managed using the traditional open, anterior approach.**

25%; and pheochromocytoma, 25%). Mean operating time was 168 minutes; hospital stay, 3 days; and return to normal activities, 4.6 days. Ninety-three percent of patients had no perioperative complications, 4% had transient procedure-related complications, and 3% had perioperative complications unrelated to the technical aspects of the procedure itself. No perioperative deaths occurred.

The cure rates for primary aldosteronism, Cushing's syndrome, and pheochromocytoma have been identical in both open and laparoscopic cohorts at Mayo Clinic. Between 1995 and 1998, 19 patients underwent bilateral laparoscopic adrenalectomy for Cushing's syndrome. Sixteen of these were completed laparoscopically, 12 of which were pituitary-dependent and 4 were related to ectopic corticotropin production. The mean follow-up was 32 months in these patients. Signs and symptoms of Cushing's syndrome resolved in all patients, particularly proximal myopathy, hirsutism, and emotional lability. All patients had improved blood pressure and glucose tolerance and considerable weight loss. No residual cortisol secretion was identified in any of these patients.

Mayo Clinic endocrine surgeons have also used laparoscopic adrenalectomy in the management of selective cases of congenital adrenal hyperplasia (CAH). This approach is a reasonable alternative for select patients with severe CAH, especially those who are known salt wasters and are already taking mineralocorticoids. Bilateral laparoscopic adrenalectomy eliminates the need for supraphysiologic doses of glucocorticoids, as well as the need for androgen-receptor blocking agents.

Laparoscopic adrenalectomy has also been used

at Mayo Clinic to manage pheochromocytomas in patients with familial disorders such as von Hippel-Lindau disease and neurofibromatosis. Cortical-sparing adrenalectomy is possible laparoscopically with the aid of laparoscopic ultrasonography and the use of the ultrasonic dissecting shears. In most instances, this treatment has allowed patients to avoid exogenous corticosteroid dependency.

Because of the availability of laparoscopic adrenalectomy, Mayo Clinic surgeons have also been strong advocates of unilateral adrenalectomy in patients diagnosed as having multiple endocrine neoplasia type 2 (MEN2) but without obvious bilateral disease. Whether cortical-sparing adrenalectomy is appropriate in MEN2 patients remains to be determined, given theoretical concerns over transecting an adrenal medulla with medullary hyperplasia.

Laparoscopic adrenalectomy has become the standard surgical approach at experienced endocrine centers for most patients with smaller benign, functioning and nonfunctioning adrenal neoplasms. Adrenocortical carcinomas have been considered a contraindication to laparoscopic adrenalectomy at Mayo Clinic, and an open anterior approach is favored for obvious cancers. An open approach facilitates dissection of contiguous structures to better sample lymph nodes and to better avoid tumor spillage with larger tumors.

If you have questions about laparoscopic adrenalectomy or if you have a patient you think might benefit from consultation with an endocrinologist and an endocrine surgeon at Mayo Clinic, a facilitated appointment can be made by calling 800-313-5077.

## Graves' Ophthalmopathy: Medical vs Surgical Treatment of Severe Disease

Clinically evident Graves' ophthalmopathy (GO) occurs in approximately 20% of patients with Graves' disease and is evident in approximately 90% of patients if CT or MRI is used to establish the diagnosis. Fortunately, less than 5% of patients with Graves' disease have severe GO. The natural history of GO is characterized by a period of progression over 3 to 6 months, a plateau phase lasting a few months to several years, and then gradual but incomplete improvement. Overall, two-thirds of patients with mild GO not receiving disease-modifying eye therapy show spontaneous improvement over a 12-month period, and in about 10% their condition deteriorates.

Several studies have reported a striking association between cigarette smoking and GO. In addition, smoking is associated with aggravation of eye disease after radioiodine therapy and adversely influences the course of GO during treatment with corticosteroids and orbital radiotherapy.

The most important factors in prevention of onset or progression of Graves' eye disease appear to be early and accurate control of thyroid dysfunction and counseling the patient to refrain from smoking. In general, thyrotoxicosis in Graves' patients without clinically evident eye disease is best treated using radioiodine without concurrent

### Points to Remember

- **Patients with Graves' ophthalmopathy (GO) are best treated collaboratively by an endocrinologist and an ophthalmologist.**
- **Early and complete control of hyperthyroidism and counseling patients to refrain from smoking are important in the management of GO.**
- **Immunosuppressive medical therapy is generally most successful in patients with inflammatory disease of short duration.**
- **Decompression surgery is effective treatment for optic neuropathy, severe proptosis, and orbital congestion and in patients who are unresponsive to or intolerant of immunosuppressive therapy.**

corticosteroids because the risk of progression in this group of patients is low. In patients with established eye disease, especially smokers, the combined use of radioiodine and corticosteroids should be considered. The equivalent of 40 to 60 mg of prednisone daily beginning on the day that radioiodine is given, with a taper over 4 to

### Clinical Update

*Clinical Update* Produced  
by Mayo Clinic  
200 2nd Street SW  
Rochester, MN 55905

**Medical Editor**  
Scott C. Litin, MD

**Endocrinology  
Special Edition  
Medical Editor**  
William F. Young, Jr, MD

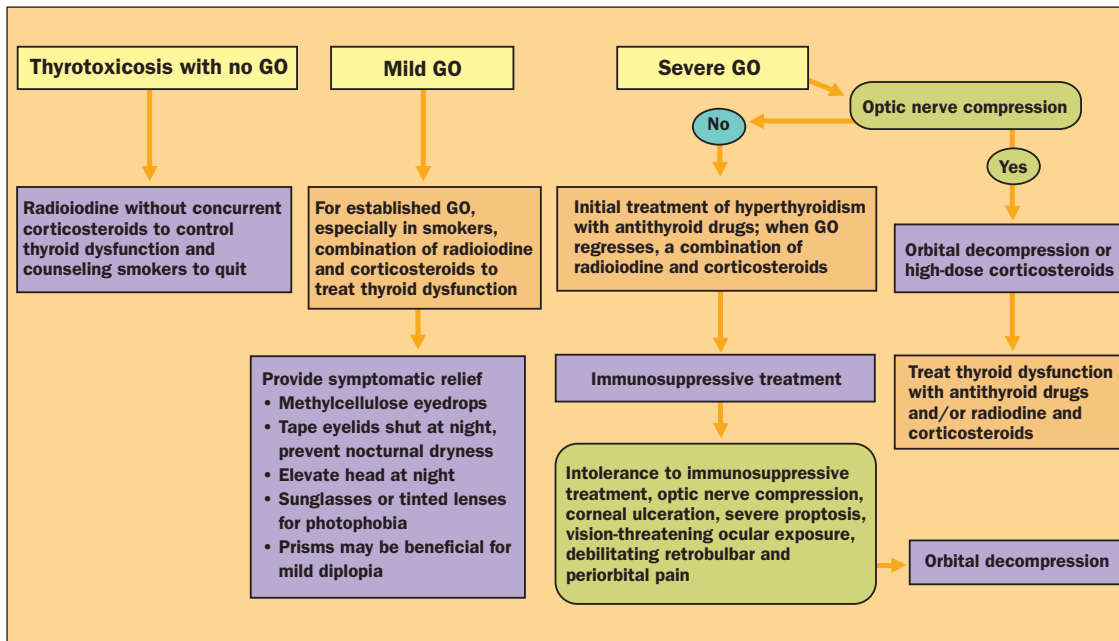
**Production Manager**  
Carol F. Lammers

**Science Writer**  
Anne D. Brataas

**Art Director**  
Ron O. Stucki

**Production Designer**  
Connie S. Lindstrom

**Distribution Manager**  
Laurie L. Wilshusen



**Figure 1.** Approach to the treatment of Graves' ophthalmopathy (GO) and associated thyrotoxicosis.

6 weeks, is generally used for prophylaxis.

Most patients with GO have a self-limited and mild disease course that requires only local measures for symptomatic relief. These patients have modest periorbital and eyelid edema, intermittent diplopia, photophobia, and a sensation of mild ocular irritation or dryness. Symptoms resulting from corneal drying are effectively treated with instillation of methylcellulose-containing eyedrops and taping the eyelids shut at night to prevent nocturnal corneal drying. Worsening of diplopia and soft tissue changes at night result from dependent edema, which may respond to elevation of the head. The use of sunglasses or tinted lenses may assist in decreasing photophobia. Prisms are occasionally useful for the correction of mild diplopia.

Patients with severe periorbital edema, proptosis, eye pain, changes in visual acuity or color vision, or severe restriction of ocular motion should be assessed by an ophthalmologist to determine whether they need emergent surgical treatment for compressive optic neuropathy or corneal ulceration. If no early surgical intervention is needed, the patient may benefit from a course of immunosuppressive therapy. Oral corticosteroids are effective in approximately two-thirds of patients with GO, especially those having particularly

inflammatory eye disease. This modality provides rapid relief from the pain, injection, and conjunctival edema associated with the inflammatory soft tissue changes in patients with active GO. Corticosteroid therapy is generally initiated with a relatively high dose, such as 40 to 80 mg of prednisone per day. After 2 to 4 weeks, the daily dose is tapered by 2.5 to 10.0 mg every 2 to 4 weeks. In many instances, drug withdrawal results in exacerbation, which requires increases in dosage and a slower rate of subsequent taper. Figure 1 summarizes treatment approaches for patients with GO.

Soft tissue inflammation begins to improve within 1 to 2 days of corticosteroid therapy, and typical courses range from 3 to 12 months. Pulse therapy with intravenous methylprednisolone, using 3 doses of 500 mg on alternate days intravenously followed by an oral regimen, has also been effective in patients with GO. A recent study at Mayo Clinic cast doubt on the effectiveness of orbital radiotherapy alone for treatment of GO. In this prospective, randomized, double-blind, placebo-controlled study, no clinically significant beneficial effect was seen using orbital radiotherapy alone in patients with moderately severe disease. However, the potential benefit of orbital radiotherapy alone or in combination with corticosteroids in selected patients, especially those with particularly inflammatory or severe disease, awaits further study.

Mayo Clinic investigators are currently recruiting patients with GO to participate in a trial to determine the effectiveness of a long-acting analogue of octreotide in the treatment of patients with severe GO.

Patients with severe but relatively inactive disease or those who are unresponsive or intolerant of immunosuppressive treatment might benefit from orbital decompression surgery. The orbit is decompressed by removing one or more of its bony walls, which expands the eye socket and increases the potential space for the orbital



**To make an appointment** for a patient in the Division of Endocrinology, Diabetes, Metabolism, and Nutrition at Mayo Clinic in Rochester, use this toll-free number: **800-313-5077**

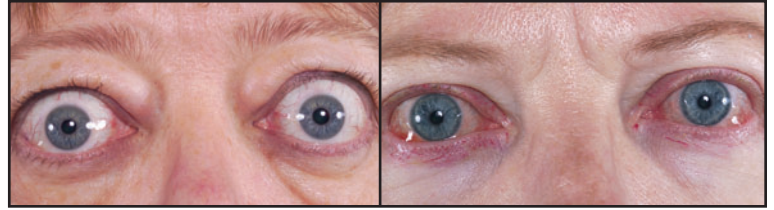
MC2024-0105

contents. Indications for the procedure include optic neuropathy, severe proptosis (which in some patients may cause subluxation of the globe anterior to the eyelids), vision-threatening ocular exposure, and debilitating retrobulbar and periorbital pain. Additionally, because some extraocular muscle procedures used in patients with GO may worsen exophthalmos, preliminary orbital decompression may be useful in those with severe proptosis. Finally, orbital expansion may be considered in patients who do not have functional ocular disease but desire enhanced cosmesis.

Optic neuropathy is the most common indication for orbital decompression at Mayo Clinic. It is important to recognize that patients with optic neuropathy often have less exophthalmos than do patients without optic nerve compromise because proptosis may function as the body's way of "autodecompressing" the orbit. Some patients with optic nerve compression can be effectively treated with high-dose corticosteroids (eg, 120-mg prednisone taper or intravenous methylprednisolone followed by oral prednisone taper).

In all patients thyroid hormone levels are generally restored to normal before any type of orbital surgery is performed. An exception to this is very severe GO threatening a patient's vision, which may require urgent orbital decompression.

Eyelid surgery for GO and strabismus procedures are typically performed after orbital



**Patients with severe Graves' ophthalmopathy. The patient on the left, with extreme proptosis, corneal ulceration, lid retraction, and extraocular muscle dysfunction, would likely benefit from orbital decompression surgery followed by extraocular muscle and eyelid surgery. The patient on the right, with very active inflammatory GO, would likely respond to corticosteroid therapy.**

decompression. The retractors of the upper eyelid, the levator palpebrae superioris muscle and Müller's muscle, undergo pathologic changes similar to those seen in the extraocular muscles. Upper eyelid retraction is relieved by weakening (recessing) the muscles; lower lid retraction is treated with analogous procedures, although spacers of hard palate mucosa, tarsus, donor sclera, or cartilage are often grafted into the lids to counteract the tendency of gravity to pull the lids inferiorly during the postoperative period. Blepharoplasty (removal of excess eyelid and orbital tissue that prolapses anteriorly from the increase in orbital volume) may be of additional cosmetic benefit in selected patients.

If you have questions about the treatment of Graves' ophthalmopathy or if you have a patient you think might benefit from consultation with an endocrinologist and an ophthalmologist at Mayo Clinic, a facilitated appointment can be made by calling 800-313-5077.



200 First Street SW  
Rochester, Minnesota 55905  
[www.mayoclinic.org](http://www.mayoclinic.org)

© 2004, Mayo Foundation for Medical Education and Research (MFMER). All rights reserved.  
MAYO, MAYO CLINIC and the triple-shield Mayo logo are trademarks and service marks of MFMER.

NON-PROFIT  
ORGANIZATION  
U.S. POSTAGE PAID  
ROCHESTER, MN  
PERMIT NO. 259