



## Uveal Melanoma Research and Treatment at Mayo Clinic

### INSIDE THIS ISSUE

- 2 New Glaucoma Research Increases Understanding of Human Conventional Outflow
- 3 Retina Photography Project Ensures Early Detection and Treatment of Diabetic Retinopathy
- 4 Research Confirms Association Between *TCF4* Gene and Fuchs Corneal Dystrophy

Mayo Clinic in Rochester, Minnesota, has a long history in the treatment of uveal melanomas. In the early 1980s, Dennis Robertson, MD, was one of the first to use iodine-125 plaques, the form of brachytherapy most commonly used for treatment of uveal melanomas in the United States today.

The plaques used in the Collaborative Ocular Melanoma Study (COMS), a multicenter study initiated in 1985 to evaluate therapeutic interventions for patients with choroidal melanoma, used gold shells made at Mayo Clinic. COMS showed that treatment of medium-sized choroidal melanomas (Figure 1) with radioactive plaque brachytherapy was at least 90% successful in local control of the melanoma and had no increase in metastatic risk compared with enucleation. Unfortunately, radiation retinopathy ultimately limits vision in these patients.

"The question now, however, is what to do with small, medium, and large melanomas in light of COMS data and new molecular information," said Jose S. Pulido, MD, of the Department of Ophthalmology. At least 50% of uveal melanomas have a mutation in a protein called GNAQ. Unfortunately, this mutation occurs early on, even in what are considered choroidal nevi. Of more importance is that there appear to be 2 forms of uveal melanomas:

- Class 2, a uveal melanoma associated with monosomy of chromosome 3 and with mRNA that confers a high metastatic risk
- Class 1, a uveal melanoma with disomy 3 or mRNA testing that has a low metastatic risk

"Patients are attuned to these distinctions. Many wish to undergo prognostic testing. It is important to carefully discuss the results and use of the data with patients because at this time there is no prophylactic treatment for clinically undetectable but high-risk uveal melanomas," according to Dr Pulido. These questions are a focus of intense

research at Mayo Clinic and other institutions.

### Treatment for Large Uveal Melanomas

Although COMS recommended enucleation for large uveal melanomas, recently such tumors have been treated with larger radioactive plaques, especially if the patient has type 2 melanoma with a poor prognosis. Despite a higher risk of local recurrence and poor vision from radiation retinopathy, local treatment may be a reasonable option because the eye and useful vision are retained for some time.

Radiation retinopathy has been a considerable problem with brachytherapy. Methods of obtaining good local control by combining treatment methods may decrease the development of this complication. Intraoperative ultrasound for precise localization of the plaque in association with combination therapy may be helpful in this regard. Research is in progress to find methods of maintaining local control while minimizing vision loss.



Jose S. Pulido, MD

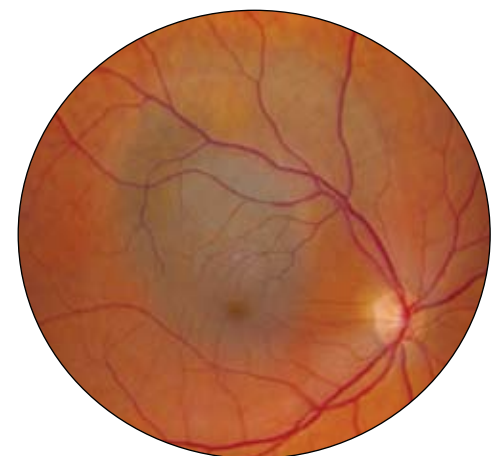
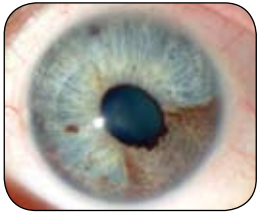
Figure 1. Choroidal melanoma.



**Figure 2.** *Iris melanoma.*

### New Research

A study conducted by Dr Pulido in collaboration with the Department of Radiation Oncology evaluated a new plaque design that allows for in situ radiation of an iris melanoma (Figure 2). This innovation precludes removal of the melanomas, yet decreases the amount of radiation to other portions of the eye.

Additional studies conducted with the Department of Molecular Medicine and the Department of Immunology aim to induce autoimmunity for the treatment of ocular melanomas. Initial animal studies have shown promise, and methods to adapt this approach for human trials are in progress.

## New Glaucoma Research Increases Understanding of Human Conventional Outflow



*Michael P. Fautsch, PhD*

In 1873, German ophthalmologist Theodor Leber postulated that elevated intraocular pressure (IOP) in the glaucomatous eye resulted from increased outflow resistance to aqueous humor drainage. It is widely accepted that the likely site of outflow resistance resides between the juxtacanalicular region of the trabecular meshwork (TM) and the inner wall of the Schlemm canal, but identification of the regulatory mechanisms and molecules within this area has been elusive.

Increase in TM cell contractility, permeability, and different forms of stress are a few of the mechanisms believed to increase outflow facility in primary open-angle glaucoma (POAG). Understanding the pathophysiology of outflow resistance in normal and POAG eyes is essential for the identification of key molecules that can be used as novel therapeutic targets.

Michael P. Fautsch, PhD, of the Department of Ophthalmology at Mayo Clinic in Rochester, Minnesota, and his laboratory team are conducting several innovative studies to identify the molecular events involved in IOP modulation, including identification of novel prostaglandin analog cell signaling targets and aqueous humor flow through the conventional outflow pathway.

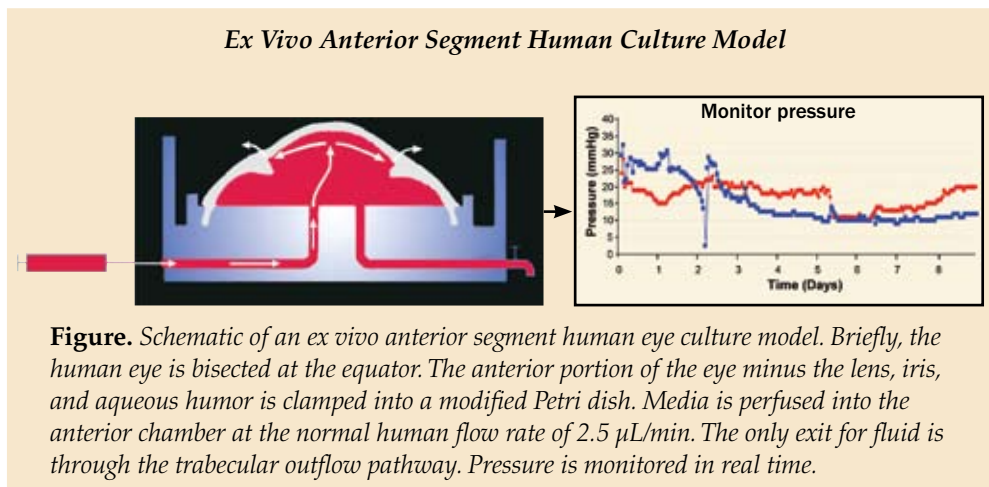
### Prostaglandin Analog Cell Signaling

Prostaglandin analogs such as latanoprost are among the first-line treatments for lowering IOP, but their mode of action at the molecular level is unknown. Until recently it was thought that prostaglandin analogs acted solely through the uveoscleral pathway.

Using an ex vivo anterior segment human eye culture model developed at Mayo Clinic, researchers have demonstrated that prostaglandin analogs increase outflow facility through the conventional or trabecular outflow pathway in addition to the uveoscleral pathway (Figure).

Using several prostaglandin analogs, multiple primary TM cell lines, and different treatment durations, Dr Fautsch's research team has identified several proteins involved in prostaglandin analog signaling. One of these proteins is calcipressin, an inhibitor of calcineurin, a serine-threonine phosphatase protein involved in several calcium-dependent cellular signaling pathways. Treatment with cyclosporine, an inhibitor of calcineurin activity, increased outflow facility in the ex vivo anterior segment human eye culture model, suggesting a role for calcipressin and calcineurin in IOP control.

Ongoing studies aim to identify regulatory proteins downstream to calcipressin and calcineurin. The goal is to identify these molecules and develop therapeutics to regulate their activity, leading to better control of IOP.



### Aqueous Humor Outflow Pathway

Classical understanding of the aqueous humor outflow pathway focuses on homogenous fluid movement through the TM. This focus is partly due to lack of human models and the

ability to visualize fluid movement in real time.

Mayo Clinic researchers have found that aqueous flow through the TM is not uniform but is increased in regions of the TM underneath the collector channels. These preferential fluid flow regions are associated with expanded TM (specifically the juxtacanalicular tissue) found directly under collector channels.

Mayo researchers are using 3-dimensional micro-computed tomography to study the conventional outflow pathway as a functional unit. This imaging modality enables identification of the collector channel location, size, and associated episcleral veins down to 2-micrometer resolution.

Preliminary work has indicated that the orifice size of collector channels in POAG eyes may be reduced by as much as 50% compared with normal collector channel orifices. This finding is important because the reduction in collector channel orifice size would have a profound effect on outflow resistance. Determining

whether the change in orifice size is a cause or effect in glaucoma is a new direction for Dr Fautsch's research team.

### **New Ideas, Approaches, and Questions**

It has been more than 130 years since Dr Leber's astute recognition that elevated IOP is the result of increased outflow resistance to aqueous drainage. New approaches are beginning to dissect the molecular and anatomic features associated with POAG. Many questions, however, still require answers. Researchers at Mayo Clinic currently work to

- Determine the effect of prostaglandin analogs in normal and POAG eyes.
- Identify the molecular mechanisms responsible for coupling prostaglandin analog to increased trabecular outflow facility.
- Understand how changes in the trabecular outflow pathway, such as collector channel orifice size, affect outflow facility.

## **Retina Photography Project Ensures Early Detection and Treatment of Diabetic Retinopathy**

Despite the availability of effective treatment for diabetic retinopathy for nearly 3 decades, early detection is still critical to prevent vision loss. The Department of Ophthalmology and the Mayo Employee Health Service in Rochester, Minnesota, have teamed to ensure that Mayo Clinic employees with diabetes keep watch on their vision.

The retina photography project alerts diabetic patients to signs of eye disease so that they can receive early treatment and avoid potential vision loss. At selected Mayo primary care clinics, technicians use cameras to provide a retinal photograph that can detect the earliest signs of diabetic eye disease. Photographs may be obtained when employees are seeing their primary care physicians for regular diabetic management.

Following an established dilation protocol that includes visual acuity testing and applanation tension, technicians acquire 30° color fundus photographs centered on both the macula and the optic nerve. The retinal scans are transferred electronically through a secure portal to the Department of Ophthalmology, where they are interpreted by Andrew J. Barkmeier, MD, a vitreoretinal specialist. If Dr Barkmeier sees any indication of diabetic eye disease, the patient is offered a complete eye examination and transferred from the photographic screening program to a periodic examination area in the ophthalmology department. The retinal scans also become a permanent

part of each patient's electronic medical record.

### **The Goal: 100% Participation Annually**

Nationwide, less than 50% of people with diabetes have yearly eye examinations, often because eye care is not controlled by the primary care physician or diabetes specialist. Project leaders hope that by providing convenient access to retinal photographs in the primary care setting, they can increase the rate of annual eye examinations for Mayo employees with diabetes to 100%.

The retina photography project is directed at diabetic patients who have relatively good control of their diabetes and may not feel a need to schedule annual eye examinations. Rajeev Chaudhry, MBBD, a primary care physician, and Dr Barkmeier agree that patients today are generally well educated about diabetes and the need to monitor blood glucose levels. Many patients, however, do not appreciate the seriousness of diabetic retinopathy and do not see an ophthalmologist until they have symptomatic vision loss.

The cost of a fundus camera and associated hardware and software is approximately \$25,000 per site. Photographic screening for diabetic eye disease is not reimbursed by Medicare, Medicaid, or most commercial payers. Project leaders anticipate, however, that task transfer associated with new technology, convenient access, and ophthalmology oversight will improve diabetic retinopathy screening efficacy and reduce costs.



*Andrew J. Barkmeier, MD*



*Ophthalmology Update* is written for physicians and should be relied upon for medical education purposes only. It does not provide a complete overview of the topics covered and should not replace the independent judgment of a physician about the appropriateness or risks of a procedure for a given patient.

## Contact Us

You don't need to request a consult from a specific physician to refer a patient. We'll help you reach the most appropriate contact.

**Arizona**  
866-629-6362

**Florida**  
800-634-1417

**Minnesota**  
507-284-2744

[www.mayoclinic.org/medicalprofs](http://www.mayoclinic.org/medicalprofs)

## Research Confirms Association Between *TCF4* Gene and Fuchs Corneal Dystrophy

Fuchs corneal dystrophy (FCD) accounts for the majority of corneal grafts performed at Mayo Clinic in Rochester, Minnesota and is the most common indication for corneal transplantation in the United States (Figure). Corneal guttae, the hallmark of FCD, are present in approximately 5% of individuals over the age of 40 years.

Until recently, investigations into the genetic causes of FCD revealed a few genes that are rare causes of the dystrophy. A research team that includes Keith H. Baratz, MD,



William L. Brown, OD

and William L. Brown, OD, of the Mayo Clinic Department of Ophthalmology and collaborators at the University of Oregon and University of Michigan, however, has discovered a strong association between the transcription factor 4 gene (*TCF4*) on chromosome 18 and FCD.

A genome-wide association study (GWAS) compared 100 affected study participants with 200 controls. GWAS techniques identify genetic variation of individual alleles, or single nucleotide polymorphisms, at thousands of sites along the entire genome.

"This study allowed a simultaneous comparison of 330,000 alleles between the affected and unaffected subjects. The strength of the association between FCD and variation at the *TCF4* gene was unprecedented. The *TCF4* gene may be responsible for 75% of FCD," says Dr Baratz. The results of the initial GWAS were confirmed in an additional 160 Mayo patients affected by FCD.

"This finding is a major advance in understanding the cause of FCD. Once the primary gene is known, research can elucidate the pathophysiology and treatment of the disease. Newer corneal transplantation techniques are very good, but not perfect. It would be great to have an alternative to halt progression in patients identified with an early stage of the disease," according to Dr Baratz.

### E2-2 Protein Function Varies

*TCF4* encodes the E2-2 protein, which is in the class of basic helix-loop-helix proteins. These proteins regulate the expression of other genes, controlling tissue differentiation and differential expression of tissue-specific proteins.

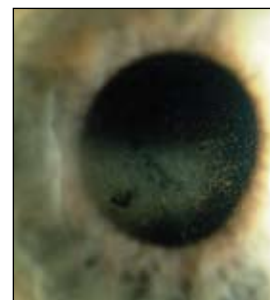
The function of E2-2 in the eye is not known, but in other tissues, the protein participates in diverse biochemical pathways. E2-2 has been implicated both as a tumor suppressor, by inhibiting the cyclin-dependent kinase pathway, and as a tumor promoter, through E2-2 control of epithelial-to-mesenchymal transition.

Tumor promoters involve a complex array of pathways that influence the balance between tissues with an epithelial phenotype, including apicobasal polarity, basement membrane production, and strong intercellular junctions, and tissues with a mesenchymal phenotype. Mesenchymal characteristics, which are typical of invasive tumors, include a loss of polarity and a disorganized growth pattern.

Dr Baratz notes: "One of the causes of cancer may also play a role in FCD. The disease may result from a complex alteration in the differentiation or phenotypical expression of corneal endothelial cells. This process is a lot more interesting than the simple equation of 1 gene resulting in 1 abnormal protein. It also presents a much bigger challenge in defining FCD on a molecular level. Eye research doesn't get any more exciting than this."



Keith H. Baratz, MD



**Figure.** Fuchs corneal dystrophy is the most common indication for corneal transplantation in the United States.



4500 San Pablo Road  
Jacksonville, FL 32224

200 First Street SW  
Rochester, MN 55905

13400 East Shea Boulevard  
Scottsdale, AZ 85259

MC2024-1210

[www.mayoclinic.org](http://www.mayoclinic.org)