

## Distal Humerus Fractures and Nonunions

### *Advanced Fixation Techniques and Replacement Surgery Solve a Challenging Problem*



**Daniel J. Berry, MD**  
Medical Editor and  
Chair, Mayo Clinic  
Department of  
Orthopedic Surgery

#### INSIDE THIS ISSUE

**3** New Knee Dislocation Study Group Defines Systematic Approach to Controversial Dislocations, Multiligament Injuries

**6** Success in Replacing the Metacarpophalangeal Joints and Ulnar Head

Most orthopedic surgeons feel somewhat challenged when faced with a complex distal humerus fracture or an established distal humerus nonunion (Figure 1). Obtaining optimal functional outcomes for these patients has traditionally been difficult for multiple reasons. Chief among them are the facts that comminution and bone deficiency complicate reconstructive surgery in an anatomic area with intricate geometry and a high propensity to stiffness and poor function.

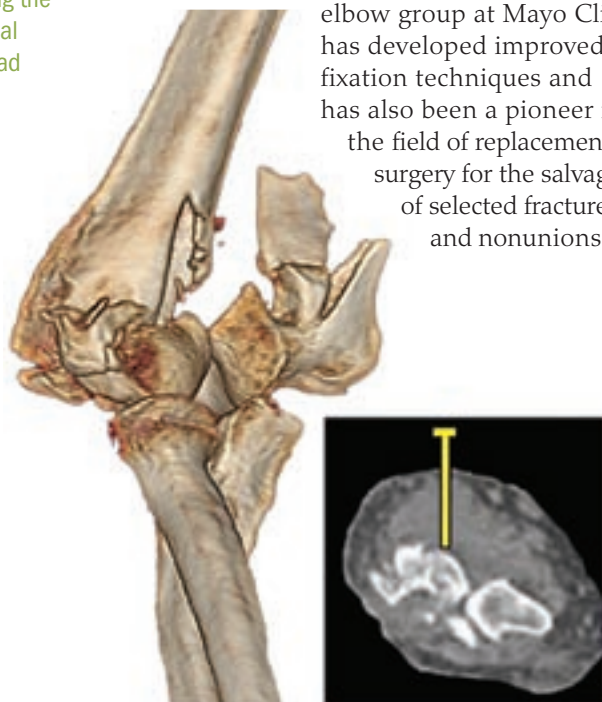
"Many patients are left with either a stiff, dysfunctional elbow or a nonunion with gross instability," explains Joaquin Sanchez-Sotelo, MD, PhD, an orthopedic surgeon specializing in elbow surgery at Mayo Clinic in Rochester, Minnesota. "Fortunately, our elbow group at Mayo Clinic has developed improved fixation techniques and has also been a pioneer in the field of replacement surgery for the salvage of selected fractures and nonunions.

These 2 advances have changed the way distal humerus fractures and nonunions are treated all over the world."

#### **An Improved Principle-Based Fixation Strategy**

Orthopedic surgeon Shawn W. O'Driscoll, MD, PhD, developed the principle-based parallel-plating internal fixation technique for both fractures and nonunions (Figure 2). Dr Sanchez-Sotelo helped popularize the technique and independently reviewed the results obtained. "Dr O'Driscoll's technique provides surprisingly robust fixation even in complex fractures considered unfixable in the past," explains Dr Sanchez-Sotelo. "Traditional fixation techniques used in the past failed to provide sufficient stability; our technique satisfies 2 major principles: maximal fixation in the distal fragments and true compression at the supracondylar level."

The details of the principle-based internal fixation technique and the results obtained were published in the American edition of the *Journal of Bone and Joint Surgery*. In a selected



**Figure 1.** Distal humerus fractures and nonunions are characterized by severe bone destruction. Modern CT scans provide a better understanding of the complex geometry.



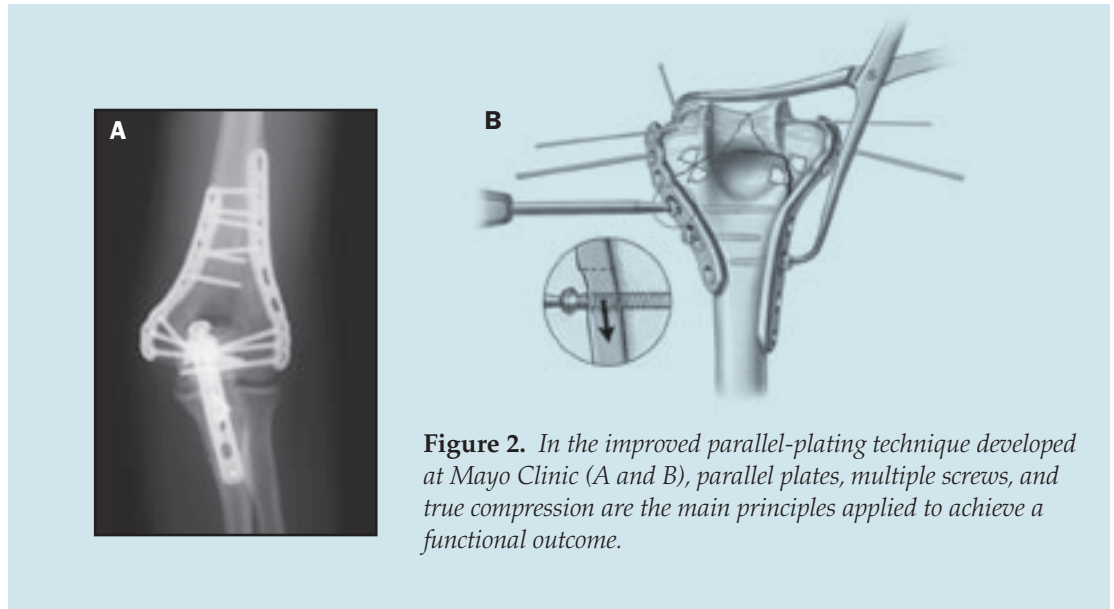
Joaquin Sanchez-Sotelo, MD, PhD



Shawn W. O'Driscoll, MD, PhD



Bernard F. Morrey, MD



**Figure 2.** In the improved parallel-plating technique developed at Mayo Clinic (A and B), parallel plates, multiple screws, and true compression are the main principles applied to achieve a functional outcome.

group of complex fractures, results show that no patients experienced hardware failure or fracture re-displacement despite an aggressive physical therapy protocol.

### Replacement as a Salvage Option

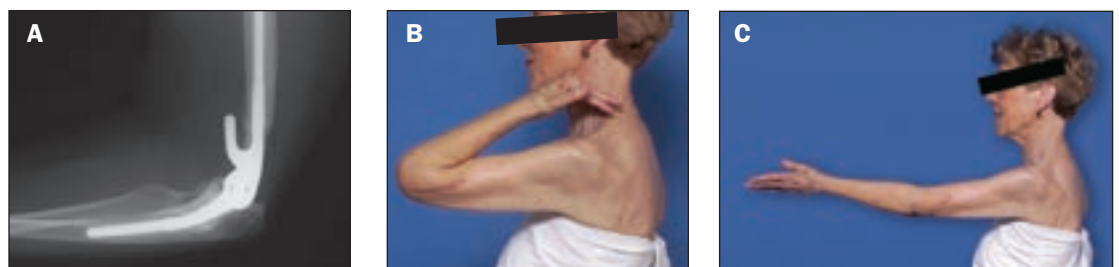
Mayo Clinic's Bernard F. Morrey, MD, pioneered the use of replacement arthroplasty for the salvage of selected fractures and nonunions (Figure 3). "Early in my career, the orthopedic community showed reluctance to perform arthroplasty for these conditions. A linked arthroplasty design and a surgical technique that does not violate the triceps provide a low-morbidity and relatively easy procedure for patients with no other alternatives," explains Dr Morrey. "We just published the long-term results of elbow arthroplasty in distal humerus nonunions, with impressive clinical results and good durability. Some patients returned 20 years after surgery with well-functioning implants," Dr Sanchez-Sotelo adds.

The study mentioned above, also recently published in the American edition of the *Journal of Bone and Joint Surgery*, included close to 100 elbow arthroplasties in patients with distal humerus nonunions who were followed for a mean of 6.5 years. Subjective satisfaction and implant survival at 5 years were both higher than 80%.

### Innovation Well Served By Team Approach

The close collaboration of 3 elbow surgeons at Mayo Clinic has resulted in the development of 2 innovative orthopedic treatment alternatives that simply did not exist in the past. Patients all over the world now benefit from improved fixation techniques and replacement surgery.

*Mayo Clinic and Dr O'Driscoll receive royalties related to development of some of the technologies mentioned in this article.*



**Figure 3.** Another attractive option for the salvage of fractures and nonunions is elbow arthroplasty (A), also pioneered at Mayo Clinic. This replacement surgery provides impressive functional outcomes (B and C) for patients with no other alternative.

## New Knee Dislocation Study Group Defines Systematic Approach to Controversial Dislocations, Multiligament Injuries

Knee dislocation caused by violent trauma is a complex, severe injury. Disruption of at least 3 of the 4 major ligaments causes pronounced instability, and the condition is typically a limb-threatening injury because of the combination of vascular and neurologic damage (Figure 1).



Michael J. Stuart, MD, and Bruce A. Levy, MD

There is a lack of high-level evidence available on which to base a systematic approach to evaluation and treatment of knee dislocation patients with multiligament injuries, despite the fact that comprehensive centers of orthopedic excellence like Mayo Clinic regularly treat numerous patients with traumatic knee dislocation. For example, a single orthopedics practitioner at Mayo Clinic has performed 91 cases in the past 3 years.

The unsettled questions and controversies these cases present center on several factors: treatment approach, timing of surgery, selection of grafts for reconstructing ligaments, and

postoperative care. Each case is highly individual and the surgical procedures are complex (Figure 2).

### The Power of a Study Group

To fill the evidence gap and create better outcomes for more patients by achieving a consensus on best practices, a group of 8 knee surgery specialists from the United States and Canada formed the Knee Dislocation Study Group. The impetus for this international effort came from Mayo Clinic's Bruce A. Levy, MD, an orthopedic surgeon on the Rochester, Minnesota, campus. Dr Levy was inspired by the clinical successes that resulted after the Canadian Orthopaedic Trauma Group pooled experiences from multiple institutions. The Knee Dislocation Study Group convened its first working session in September 2007.

Explains Dr Levy: "No 2 knee dislocations are exactly alike—except that the decision making involved is always highly challenging. Because of this fact, I found myself reaching out to my mentors for guidance. It was immediately obvious that everybody involved benefits from such a group—all the orthopedic surgeons and all the patients. By pooling our experience and our data, we produce evidence that is more powerful for devising a systematic approach to obtaining optimal outcomes for knee dislocation patients."

Adds Michael J. Stuart, MD, Dr Levy's Mayo Clinic collaborator: "The power of the group is

*Continued on page 7*

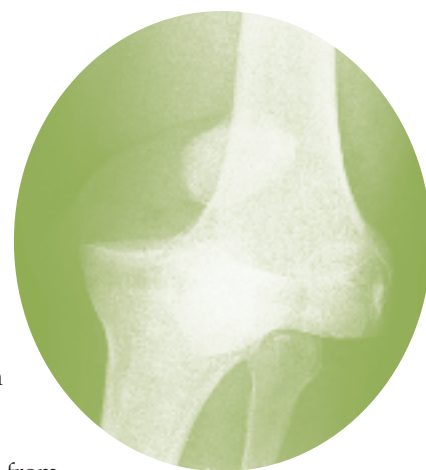


Figure 1. Preoperative anteroposterior radiograph of a knee dislocation.

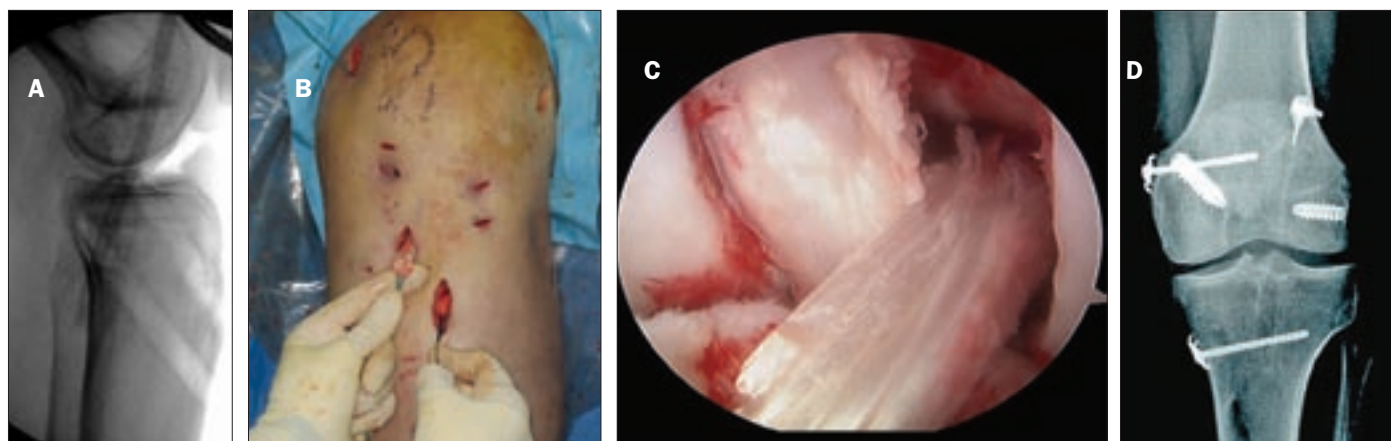


Figure 2. A, Intraoperative fluoroscopic lateral view demonstrating anterior cruciate ligament (ACL) and posterior cruciate ligament (PCL) tunnel position. B, Intraoperative photograph of the same patient demonstrating the ACL and PCL grafts before tibial fixation. C, Arthroscopic view of the ACL and PCL grafts after fixation. D, Anteroposterior radiograph taken after multiligament knee reconstruction. C and D, Reprinted with permission from the Journal of the American Academy of Orthopaedic Surgeons, Volume 17 (4), pp 197-206.

# Mayo Clinic Orthopedic Research

## Published Highlights

### Arm, Elbow

Adams, J.E., T.L. Hoskin, B.F. Morrey, and S.P. Steinmann, Management and outcome of 103 acute fractures of the coronoid process of the ulna. *Journal of Bone & Joint Surgery – British Volume*, 2009. 91B(5): 632-635

Cil, A., S. Merten, and S.P. Steinmann, Immediate active range of motion after modified 2-incision repair in acute distal biceps tendon rupture. *American Journal of Sports Medicine*, 2009. 37(1): 130-135.

### Bone Regeneration and Transplant

Kempen, D.H.R., L.C. Lu, A. Heijink, T.E. Hefferan, L.B. Creemers, A. Maran, M.J. Yaszemski, and W.J.A. Dhert, Effect of local sequential VEGF and BMP-2 delivery on ectopic and orthotopic bone regeneration. *Biomaterials*, 2009. 30(14): 2816-2825.

### Brachial Plexus

Elhassan, B., A. Bishop, and A. Shin, Trapezius transfer to restore external rotation in a patient with a brachial plexus injury: a case report. *Journal of Bone & Joint Surgery – American Volume*, 2009. 91(4): 939-944.

Carlsen, B.T., A.T. Bishop, and A.Y. Shin, Late reconstruction for brachial plexus injury. *Neurosurgery Clinics of North America*, 2009. 20(1): 51-64, vi.

### Foot/Ankle

Blitz, N.M., K.K. Amrami, and R.J. Spinner, Magnetic resonance imaging of a deep peroneal intraneural ganglion cyst originating from the second metatarsophalangeal joint: a pattern of propagation supporting the unified articular (synovial) theory for the formation of intraneural ganglia. *Journal of Foot & Ankle Surgery*, 2009. 48(1): 80-84

### Hand

Rizzo, M., S.L. Moran, and A.Y. Shin, Long-term outcomes of trapeziometacarpal arthrodesis in the management of trapeziometacarpal arthritis. *Journal of Hand Surgery – American Volume*, 2009. 34(1): 20-26.

Elhassan, B.T. and A.Y. Shin, Vascularized bone grafting for treatment of Kienbock's disease. *Journal of Hand Surgery – American Volume*, 2009. 34(1): 146-154.

Amadio, P.C., What's new in hand surgery. *Journal of Bone & Joint Surgery – American Volume*, 2009. 91(2): 496-502.

Hoxie, S.C., J.A. Capo, D.G. Dennison, and A.Y. Shin, The economic impact of electric saw injuries to the hand. *Journal of Hand Surgery – American Volume*, 2009. 34A(5): 886-889.

Gelfman, R., L.J. Melton III, B.P. Yawn, P.C. Wollan, P.C. Amadio, and J.C. Stevens, Long-term trends in carpal tunnel syndrome. *Neurology*, 2009. 72(1): 33-41.

### Hip

Yue, E.J., M.E. Cabanela, G.P. Duffy, M.G. Heckman, and M.I. O'Connor, Hip resurfacing arthroplasty: risk factors for failure over 25 years. *Clinical Orthopaedics & Related Research*, 2009. 467(4): 992-999.

Parratte, S., M.W. Pagnano, K. Coleman-Wood, K.R. Kaufman, and D.J. Berry, The 2008 Frank Stinchfield Award: variation in postoperative pelvic tilt may confound the accuracy of hip navigation systems. *Clinical Orthopaedics & Related Research*, 2009. 467(1): 43-49.

Batsis, J.A., J.M. Huddleston, L.J. Melton, P.M. Huddleston, F. Lopez-Jimenez, D.R. Larson, R.E. Gullerud, and M.M. McMahon, Body mass index and risk of adverse cardiac events in elderly patients with hip fracture: a population-based study. *Journal of the American Geriatrics Society*, 2009. 57(3): 419-426.

Bozic, K.J., S.M. Kurtz, E. Lau, K. Ong, T.P. Vail, and D.J. Berry, The epidemiology of revision total hip arthroplasty in the United States. *Journal of Bone & Joint Surgery – American Volume*, 2009. 90A(1): 128-133.

### Infection

Larson, A.N., R.R. Razonable, and A.D. Hanssen, Capnocytophaga canimorsus: a novel pathogen for

joint arthroplasty. *Clinical Orthopaedics & Related Research*, 2009. 467(6): 1634-1638.

### **Knee**

Bauman, R.D., D.G. Lewallen, and A.D. Hanssen, Limitations of structural allograft in revision total knee arthroplasty. *Clinical Orthopaedics & Related Research*, 2009. 467(3): 818-824.

Galat, D.D., S.C. McGovern, D.R. Larson, J.R. Harrington, A.D. Hanssen, and H.D. Clarke, Surgical treatment of early wound complications following primary total knee arthroplasty. *Journal of Bone & Joint Surgery – American Volume*, 2009. 91(1): 48-54.

Levy, B.A., G.C. Fanelli, D.B. Whelan, J.P. Stannard, P.A. MacDonald, J.L. Boyd, R.G. Marx, and M.J. Stuart, Controversies in the treatment of knee dislocations and multiligament reconstruction. *Journal of the American Academy of Orthopaedic Surgeons*, 2009. 17(4): 197-206.

Levy, B.A., K.A. Dajani, D.B. Whelan, J.P. Stannard, G.C. Fanelli, M.J. Stuart, J.L. Boyd, P.A. MacDonald, and R.G. Marx, Decision making in the multiligament-injured knee: an evidence-based systematic review. *Arthroscopy*, 2009. 25(4): 430-438.

### **Neuromuscular**

de Ruyter, G.C.W., R.J. Spinner, M.J. Yaszemski, A.J. Windebank, and M.J.A. Malessy, Nerve tubes for peripheral nerve repair. *Neurosurgery Clinics of North America*, 2009. 20(1): 91-105.

Spinner, R., H. Wang, M.N. Hebert-Blouin, J. Skinner, and K. Amrami, Sciatic cross-over in patients with peroneal and tibial intraneural ganglia confirmed by knee MR arthrography. *Acta Neurochirurgica*, 2009. 151(1): 89-98.

### **Oncology**

Fuchs, B., N. Hoekzema, D.R. Larson, C.Y. Inwards, and F.H. Sim, Osteosarcoma of the pelvis: outcome analysis of surgical treatment. *Clinical Orthopaedics & Related Research*, 2009. 467(2): 510-518.

Dozois, E.J., J.C.H. Wall, R.J. Spinner, D.J. Jacofsky, M.J. Yaszemski, F.H. Sim, S.L. Moran, R.R. Cima, D.R. Larson, M.G. Haddock, S.H. Okuno, and D.W. Larson, Neurogenic tumors of the pelvis: clinicopathologic features and surgical outcomes using a multidisciplinary team. *Annals of Surgical Oncology*, 2009. 16(4): 1010-1016.

### **Pediatrics**

Nassr, A., A.N. Larson, B. Crane, K.W. Hammerberg, P.F. Sturm, and S.M. Mardjetko, Iatrogenic thoracic outlet syndrome secondary to vertical expandable prosthetic titanium rib expansion thoracoplasty: pathogenesis and strategies for prevention/treatment. *Journal of Pediatric Orthopaedics*, 2009. 29(1): 31-34.

### **Shoulder**

Athwal, G.S., J.W. Sperling, D.M. Rispoli, and R.H. Cofield, Periprosthetic humeral fractures during shoulder arthroplasty. *Journal of Bone & Joint Surgery – American Volume*, 2009. 91(3): 594-603.

Singh, J.A., M.L. Mahowald, and S. Noorbaloochi, Intra-articular botulinum toxin A for refractory shoulder pain: a randomized, double-blinded, placebo-controlled trial. *Translational Research*, 2009. 153(5): 205-216.

Marx, R.G., P. Koulouvaris, S.K. Chu, and B.A. Levy, Indications for surgery in clinical outcome studies of rotator cuff repair. *Clinical Orthopaedics & Related Research*, 2009. 467(2): 450-456.

### **Spine**

Edmundson, S.P., K.M. Hirpara, R.S. Ryan, T. O'Malley, and P. O'Grady, Delayed presentation of carotid artery dissection following major orthopaedic trauma resulting in dense hemiparesis. *Journal of Bone & Joint Surgery – British Volume*, 2009. 91(4): 536-539.

Lee, J.Y., A. Nassr, J.C. Eck, and A.R. Vaccaro, Controversies in the treatment of cervical spine dislocations. *Spine Journal: Official Journal of the North American Spine Society*, 2009. 9(5): 418-423.

Mikhael, M.M., H.G. Bach, P.M. Huddleston, T.P. Maus, and E.F. Berbari, Multilevel diskitis and vertebral osteomyelitis after diskography. *Orthopedics*, 2009. 32(1): 60.

### **Trauma**

Sems, S.A., B.A. Levy, K. Dajani, D.A. Herrera, and D.C. Templeman, Incidence of deep venous thrombosis after temporary joint spanning external fixation for complex lower extremity injuries. *Journal of Trauma: Injury, Infection, and Critical Care*, 2009. 66(4): 1164-1166.



To learn more about Mayo Clinic's ongoing orthopedic research, visit [mayoresearch.mayo.edu/mayo/research/ortho/index.cfm](http://mayoresearch.mayo.edu/mayo/research/ortho/index.cfm)



Richard A. Berger, MD, PhD

## Success in Replacing the Metacarpophalangeal Joints and Ulnar Head

Small-bone arthroplasties involving joint implants for finger, wrist, and forearm are often a neglected topic of analyses in the broad orthopedic community, probably because of a historical association with high failure rates.

Over the past decade, innovation has helped change former failure scenarios into success stories. “The progress continues in terms of materials, design, technique, implant technology, and clinical effectiveness for small-bone joint replacements,” explains Richard A. Berger, MD, PhD, a hand surgeon at Mayo Clinic in Rochester, Minnesota. He helped devise Mayo Clinic’s modular, multi-stem and multisize prosthesis for ulnar-head replacement (Avanta uHead). Mayo Clinic hand surgeon Marco Rizzo, MD, adds: “With current advances, experienced arthroplasty teams can generally vastly improve the quality of life for patients disabled by hand pain and functional impairment from degenerative damage or trauma.”



Marco Rizzo, MD

### Mayo Clinic Leadership

In 1962, Mayo Clinic hand surgeons pioneered the field of arthroplasty of the small joints of the hand when they first used silicone metacarpophalangeal (MCP) implants in rheumatoid arthritis patients. Mayo continues to lead in both innovation and clinical application of orthopedic discovery to patient care. By doing so, Mayo Clinic hand surgeons continue to offer hope for improved function to patients with advanced arthritic conditions of the hands.

Highlights of Mayo’s contribution to the success of small-joint arthroplasty include

- **1970-present:** Development and subsequent

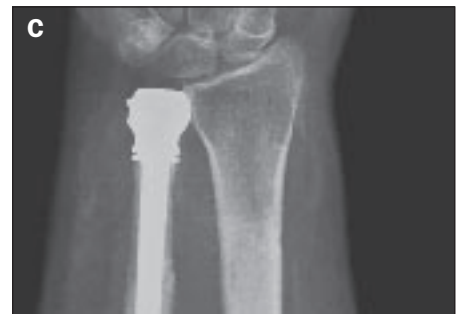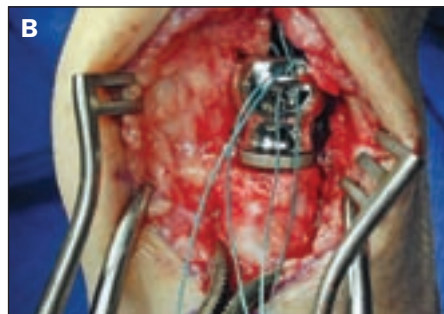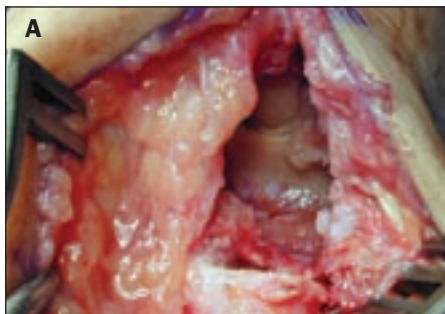
refinements to nonconstrained pyrolytic carbon implants for proximal interphalangeal joints (PIP) and MCP joints

- **1970-present:** Development and subsequent refinements of metal and plastic surface replacement implants for proximal PIP and MCP joints
- **2001:** Development of a metallic ulnar-head implant for patients with unstable forearms secondary to excision of an arthritic ulnar head
- **2007:** Development of a metal and plastic sigmoid notch component to match the ulnar-head implant to create an unlinked total joint replacement

### Rationale for Ulnar-Head Replacement

The ulnar head is central to forearm biomechanics, stability, and full wrist motion because it is the only fixed, bony, nonmoving support for radial rotation. Rheumatoid arthritis and trauma frequently impair the ulnar head and thus destroy the pain-free proper functioning of the wrist and diminish hand grip strength in older adults. In the past 10 years, advances in implants and technique have shown ulnar-head arthroplasty to be reliable, effective primary treatment when performed at centers of orthopedic excellence (Figure 1).

Replacement of the distal ulnar head may be indicated when nonoperative treatment of the wrist joint does not resolve pain, weakness, and instability, and diagnostic imaging confirms damage to the distal radioulnar joint. Additionally, evidence of failed ulnar-head resection or failed arthroplasty may indicate the need for a salvage procedure. In the presence of these indications, the patient must



**Figure 1.** A, Preparation of the “socket” for an ulnar-head implant arthroplasty. B, Securing the ulnar-head implant within the soft tissue socket. C, Anteroposterior radiograph after ulnar-head implant surgery.

also have adequate bone health and soft tissue to allow for osseous integration of the implant and tissue stabilization.

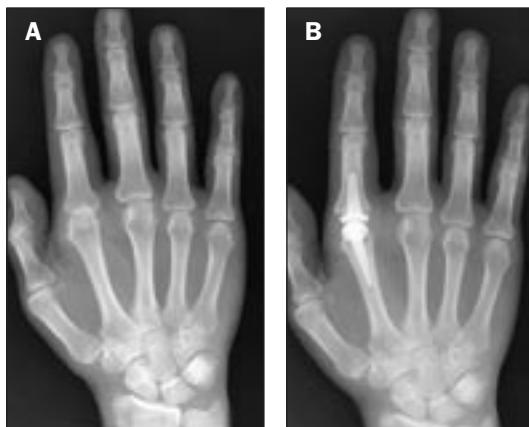### MCP Joints

Favorable results can be obtained with the newest generation of implants, nonconstrained pyrolytic carbon arthroplasty for MCP joint arthritis. As evidence, Dr Rizzo cites a published Mayo Clinic team review of 142 arthroplasties (61 patients), in which 130 were primary joint replacements (Figure 2) and 12 were revisions of prior silicone treatments.

The data showed improvements in arc of motion, oppositional pinch, and grip strength. Notes Dr Rizzo: "Preliminary results suggest that pyrolytic carbon MCP joint arthroplasty provides good pain relief, patient satisfaction, and functional improvement in managing osteoarthritis and select cases of rheumatoid arthritis." He adds that longer follow-up evaluation will help validate these promising early results.

### Expertise Creates Options

The biggest challenge now is defining the best candidates for these implants. Because of the laxity of soft tissue in severe rheumatoid arthritis patients, stability is more difficult to achieve with unconstrained implants.



**Figure 2.** Pre- and postoperative images after metacarpophalangeal implantation.

Notes Dr Rizzo: "Although the implant has worked well in selected patients with rheumatoid arthritis, those who have extensive disease, deformity, or dislocation may do better with the silicone as a fallback option. But each case is unique. It's important for patients to go to an advanced orthopedic center that can deploy all available options with equal expertise."

*Mayo Clinic and Dr Berger receive royalties related to development of some of the technologies mentioned in this article.*

## New Knee Dislocation Study Group Defines Systematic Approach to Controversial Dislocations, Multiligament Injuries

*Continued from page 3*

that we can accelerate and improve the problem-solving process. Right now, the orthopedic literature does not always provide a single, validated best approach. We hope to change that by creating evidence-based consensus."

### Goals and Visions

The group corresponds regularly and meets approximately every 6 months, often in conjunction with an annual meeting of a professional society. Members work together in the cadaver dissection laboratory to share surgical techniques; publish papers in the peer-reviewed literature; and design large multicenter research trials. They also are laying the foundation for creating a standardized database in which all their knee dislocation patients may be followed as a means of

assessing and predicting outcomes.

As an example of the clinical impact of such a study group, Dr Levy cites the Canadian group's experience with clavicle fractures. Before the group's studies and published results, most of these fractures were treated nonoperatively. But through a randomized, prospective trial comparing operative and nonoperative management, they discovered that fractures with severe displacement experienced improved functional outcomes when treated operatively. "This is tremendous work—and an example of a study group that changed clinical practice," Dr Levy says. "There really is strength in numbers. The more complex the surgery and the patient population, the more we need help from our colleagues and their pooled experience to guide our efforts to optimize patient care."

### Education

Mayo Clinic is internationally recognized for its leadership in educating hand surgeons. Five fellows a year enroll in Mayo Clinic's hand specialty program, which emphasizes cross-disciplinary collaboration.

### A Legacy of Leadership

#### Past Presidents of American Society for Surgery of the Hand

James H. Dobyns, MD  
1984-85

Ronald L. Linscheid, MD  
1989-90

William P. Cooney, MD  
1999-2000

Robert D. Beckenbaugh, MD  
1992-93

Peter C. Amadio, MD  
1998-99

Richard A. Berger, MD,  
PhD 2004-05

#### Past President of American Society for Reconstructive Microsurgery

Michael B. Wood, MD  
1991-92

### Recognition

Mayo Clinic physicians have received the Bunnell Traveling Fellowship of the American Society for Surgery of the Hand, the North American Traveling Fellowship from the American Orthopaedic Association, and the Mid-America Traveling Fellowship from the Mid-America Orthopaedic Association.

## Mayo Clinic Orthopedic Update

### Medical Editors

Daniel J. Berry, MD  
Arlen D. Hanssen, MD  
Michael J. Stuart, MD

*Orthopedic Update* is written for physicians and should be relied upon for medical education purposes only. It does not provide a complete overview of the topics covered and should not replace the independent judgment of a physician about the appropriateness or risks of a procedure for a given patient.

# Contact Us

Referrals and Consultations

### Arizona

866-629-6362

### Florida

800-634-1417

### Minnesota

Orthopedic Surgery  
507-538-4101

All Other Referrals  
and Consultations  
800-533-1564

[www.mayoclinic.org/medicalprofs](http://www.mayoclinic.org/medicalprofs)

## CME Opportunities

### Symposium on Sports Medicine

The 19th Annual Mayo Clinic Symposium on Sports Medicine will be held November 13-14, 2009, in Rochester, Minnesota. Under the leadership of course director Jay Smith, MD, and Mayo Clinic Sports Medicine Center codirectors Michael J. Stuart, MD, and Edward R. Laskowski, MD, Mayo Clinic faculty will offer live demonstrations on clinical anatomy of the hip and hip arthroscopy. The program will also include topics such as ACL injury prevention tactics; management of the unresponsive athlete; clavicle fractures; upper limb nerve injuries; and adolescent athletes with hip pain.

#### Other highlights include the following:

**Keynote speaker Stanley A. Herring, MD**, team physician for the Seattle Seahawks and the Seattle Mariners and clinical professor and medical director for spine care, University of Washington, Seattle. A nationally recognized expert in spine disorders, Dr Herring is past president of the North American Spine Society.

**Invited guest speaker William O. Roberts, MD**, a nationally recognized expert in sports medicine with a special interest in running-related injuries. Professor in the Department of Family Medicine and Community Health at the University of Minnesota Medical School, Minneapolis, Dr Roberts maintains an active clinical practice in St. Paul and serves as medical director for the Twin Cities Marathon. He is a founding member and past president of the American Road Race Medical Society.

**Invited guest speaker John F. Tomberlin, PT**, director of Mercy SportsCare and Athletic Republic Sports Performance at MercyCare Medical Center, Cedar Rapids, Iowa. A strength and conditioning specialist and fellow in the American Academy of Orthopaedic Manual Physical Therapists, he is a nationally recognized expert on adverse neurodynamic tension in athletes. He will conduct a live demonstration of clinical neurodynamic tests for the athlete's shoulder.

#### To Register

For information or to register by telephone call 800-323-2688. To register online, visit <http://www.mayo.edu/cme/sports-medicine.html>.

### International Spine Symposium

The 5th Mayo Clinic International Spine Symposium will be held January 31-February 4, 2010, in Mauna Lani Bay Hotel and Bungalows on the Big Island, Hawaii. Through interactive presentations with leaders in the field the programmatic focus centers on

- Value in spine care
- Motion preservation surgery
- Minimally invasive surgery
- Nonoperative spine care
- Spine tumors

As this issue of *Orthopedic Update* went to press, details were still being finalized. Mayo Clinic CME personnel are prepared now to answer inquiries and take reservations.

#### To Register

For information, contact Mayo School of Continuing Medical Education by phone at 800-323-2688 or e-mail at [cme@mayo.edu](mailto:cme@mayo.edu).



4500 San Pablo Road  
Jacksonville, FL 32224

200 First Street SW  
Rochester, MN 55905

13400 East Shea Boulevard  
Scottsdale, AZ 85259

MC6247-0809

[www.mayoclinic.org](http://www.mayoclinic.org)

©2008 Mayo Foundation for Medical Education and Research (MFMER).  
All rights reserved. MAYO, MAYO CLINIC and the triple-shield Mayo logo  
are trademarks and service marks of MFMER.