

Epiphyseal Growth Plate Fracture Management



Daniel J. Berry, MD
Medical Editor and
Chair, Mayo Clinic
Department of
Orthopedic Surgery

Hippocrates wrote the first medical account of fractures now known as epiphyseal growth plate fractures more than 2,400 years ago. Arrested bone growth caused by these fractures remained an accepted outcome of traumatic injury to the long bones of children until the middle of the 20th century.

In the United States, the change came in 1968, when Mayo Clinic orthopedic surgeon Hamlet Peterson, MD, first successfully resected a premature partial growth plate arrest (Figure 1; Leadership sidebar, see page 3).

So began a Mayo Clinic legacy of leadership in epiphyseal growth plate injury management. "We are fortunate at Mayo to be part of the tradition Dr Peterson began as we continue to treat partial premature growth plate arrests and provide long-term follow-up care," says Mayo pediatric orthopedic surgeon Anthony A. Stans, MD.

"This extensive experience and expertise

provides us with an excellent foundation for continually improving outcomes," adds Dr Peterson.

The Value of Longitudinal Study

The physis is an ephemeral morphologic structure of childhood. Its presence differentiates immature growing bone from mature bone. Once Dr Peterson and his colleagues confirmed that growth could be restored by physeal arrest resection, major questions related to the new procedure began to arise: What is the best surgical technique? What is the best interposition material? Will the growth arrest recur? After partial physeal arrest resection surgery does the restored growth occur at the same rate as growth in the uninjured physis of the contralateral limb? What are the side effects?

Mayo Clinic pediatric orthopedic surgeons have since helped answer these questions with longitudinal studies. Recently, they presented the

INSIDE THIS ISSUE

2 Advanced Foot Wound Management and Limb Salvage

7 Pediatric Anterior Cruciate Ligament Reconstruction: Options for Success in Skeletally Immature Patients

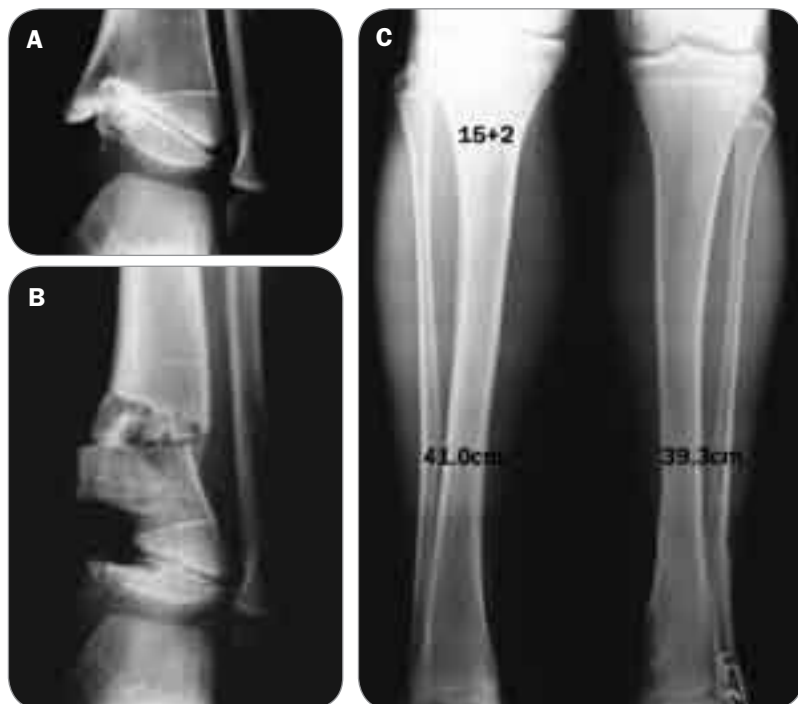

Figure 1. A, On referral to Mayo Clinic in 1968 at the age of 5 years 4 months, this patient presented with a well-established physeal bar in the distal tibia with 45° varus angulation of the physis. The left lower extremity was clinically about 3.8 cm shorter than the right. B, An intraoperative image from the first en bloc excision of the physeal bar performed in the United States. The bone removed was fashioned into a wedge and inserted in the more proximal tibial osteotomy. The cavity was lined with sheet Silastic held against the bone with Gelfoam. No internal fixation was used. C, At the age of 15 years 2 months, the patient's original leg length discrepancy was reduced by almost 2.5 cm, and the patient was normally active, asymptomatic, and well proportioned at 182 cm tall.



Hamlet Peterson, MD, and Anthony A. Stans, MD

largest follow-up study (N=100) of patients who underwent growth plate resections and were followed until they reached skeletal maturity. More than 90% of patients had some restoration of growth after growth arrest from the initial injury.

Early Is Better

These pioneering efforts in pediatric orthopedics not only help physicians restore growth when partial growth plate arrest occurs. Their work also helps physicians learn early treatment techniques for managing acute growth plate injuries that make growth plate arrest less likely to develop.

The evidence provided by Mayo's excellent outcomes has helped increase general awareness of the importance of treating growth plate injuries immediately—particularly in young children—to optimize chances of preventing permanent injury and preserving maximal growth.

From Resection to Guided Growth

Today, patients with growth plate injuries have several options for restoring growth and correcting deformities related to growth disruption.

Surgical Growth Plate Bar Resection. At experienced centers, this approach has a high success rate because advanced imaging and surgical techniques improve precision.

Guided Growth Techniques. By inserting a small (15 mm) plate during an outpatient

procedure to slow growth at a targeted site, physicians can guide growth to correct angular deformities over time. When the limb straightens, the plate is removed and normal growth resumes.

Improved External Fixator Devices. This device (eg, a Taylor Spatial Frame) allows treatment of a complex 3-dimensional deformity, should limb-length discrepancy and angular deformity occur which cannot be corrected by guided growth techniques (Figure 2). With the aid of computerized precision calculations, the device can be designed to both lengthen and straighten the limb to correct multiplanar angular deformities.

Despite remarkable advances in managing growth-arresting injuries in children, there is still no safe or reliable way to accelerate or stimulate bone growth—though many approaches have been tried.

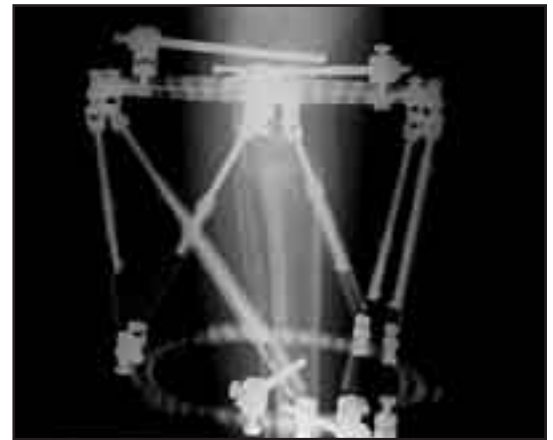


Figure 2. Five months after treatment with an external fixator, a skeletally mature patient presenting with partial premature physeal arrest sustained in a gunshot injury to the knee at the age of 9 years shows excellent regenerate bone formed across the lengthening site.

Advanced Foot Wound Management and Limb Salvage

Any wound that fails to heal within 4 weeks is considered chronic, and patients presenting with chronic ulcerations and necrotizing wounds of the lower extremities are increasingly referred to comprehensive orthopedic practices.

A major reason for this trend is the expanding patient population with diabetes mellitus and its various limb-threatening complications. An estimated 15% to 20% of diabetic patients develop foot lesions at some point, many of


which require surgical intervention to the lower extremity, such as amputating a toe, metatarsal, or forefoot, or a below-knee amputation. Moreover, foot lesions are the most common reason for which diabetic patients are hospitalized.

Multidisciplinary Management

“Numerous patients come to see us who have had nonhealing foot wounds for anywhere from 3 months to 18 months,” says Mayo Clinic podiatrist and wound specialist

Pioneering Practice

In 1968, Mayo Clinic pediatric orthopedic surgeon Hamlet Peterson, MD, became the first in the United States to successfully resect a partial premature growth plate arrest.



Hamlet Peterson, MD

Recalls Dr Peterson: “At the time, conventional wisdom held that when growth plates are damaged, there’s no restoring growth. But I had a 5-year-old patient who was at risk of losing so much growth that I talked over a resection strategy with his parents—and they agreed.”

Mayo Clinic pediatric orthopedic surgeons continue to pioneer advances in this highly specialized field. Dr Peterson has authored

the definitive textbook *Epiphyseal Growth Plate Fractures* (2007; Springer) and is now at work on the next volume addressing other types of growth plate injuries. Additional Mayo contributions include

- **devising** the Peterson classification scheme to characterize growth plate fractures and improve evaluation and management
- **documenting** the incidence and epidemiology of physal injuries
- **refining** the imaging process to locate and measure the bar to be resected
- **developing** surgical techniques for the bar excision
- **evaluating** different interposition materials for different situations

Steven J. Kavros, DPM. “Wound etiologies are multifactorial, and these patients benefit from Mayo Clinic’s multidisciplinary management approach” (Figure 1).

“Working as a team of specialists we can clear an infection, identify a blockage, remove the blockage, reconstruct vasculature, and provide rehabilitation and aftercare, all in a smooth, integrated fashion,” adds his Mayo colleague, vascular medicine specialist Thom W. Rooke, MD.

Chronic foot wounds develop in nondiabetic patients as well. In all patients, chronic wounds are treated on a medical-surgical continuum to optimize clinical outcomes that salvage limbs and restore or preserve function.

Advanced Adjunctive Wound Therapy

When a patient has had all the usual primary medical and surgical treatments and blood flow is still inadequate to support healing, Mayo Clinic physicians use key advanced adjunctive therapies with consistent success. They recommend clinicians consider the following if healing is not established in their patients by 4 weeks.

Intermittent Pneumatic Compression (IPC).

An outpatient, Medicare-reimbursable device,

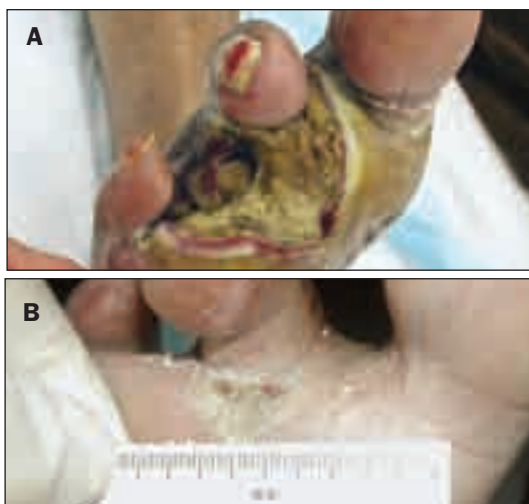

Figure 1. Before (A) and after (B) treatment of gangrenous toes demonstrates the benefits of Mayo’s multidisciplinary advanced wound management and limb salvage techniques.



Steven J. Kavros, DPM

the IPC device performs mechanical compression of the calf to remove venous congestion and promote arterial blood flow to bathe tissues with nutrients needed for wound healing. Mayo studies over the past 15 years have played a role in validating the therapeutic

Continued on page 6



Mayo Clinic Orthopedic Research

2009 Research Highlights

ACL Injury

Laundre BJ, Collins MS, Bond JR, Dahm DL, Stuart MJ, Mandrekar JN. 2009. MRI accuracy for tears of the posterior horn of the lateral meniscus in patients with acute anterior cruciate ligament injury and the clinical relevance of missed tears. *AJR American Journal of Roentgenology* 193(2):515-23.

Bone Regeneration and Transplant

Wang SF, Kempen DHR, Yaszemski MJ, Lu LC. 2009. The roles of matrix polymer crystallinity and hydroxyapatite nanoparticles in modulating material properties of photo-crosslinked composites and bone marrow stromal cell responses. *Biomaterials* 30(20):3359-70.

Dadsetan M, Knight AM, Lu L, Windebank AJ, Yaszemski MJ. 2009. Stimulation of neurite outgrowth using positively charged hydrogels. *Biomaterials* 30(23-24):3874-81.


Knee

Nesterenko S, Morrey ME, Abdel MP, An KN, Steinmann SP, Morrey BF, Sanchez-Sotelo J. 2009. New rabbit knee model of posttraumatic joint contracture: indirect capsular damage induces a severe contracture. *Journal of Orthopaedic Research* 27(8):1028-32.

Lewallen DG, Fehring TK, Dennis DA, Scuderi GR. 2009. Revision total knee arthroplasty: surgical techniques. *Journal of Bone & Joint Surgery American Volume* 91 (Suppl 5):69-71.

Pagnano MW, Argenson JN, Parratte S, Scuderi GR, Booth RE Jr. 2009. Minimally invasive total knee arthroplasty meets computer navigation. *Journal of Bone & Joint Surgery American Volume* 91 (Suppl 5):56-8.

Anderson AW, Polga DJ, Ryssman DB, Trousdale RT. 2009. The nest technique for management of a periprosthetic patellar fracture with severe bone loss. *Knee* 16(4):295-8.



Hip

Cabanela ME, Mont MA, Zywiell MG, McGrath MS. 2009. Total hip arthroplasty: case-based panel discussions. *Journal of Bone & Joint Surgery American* Volume 91 (Suppl 5):15-6.

Hanssen AD. Revision total hip arthroplasty: the painful hip." 2009. *Journal of Bone & Joint Surgery American* Volume 91 (Suppl 5):22.

Infection

Larson AN, Hanssen AD, Cass JR. 2009. Does prior infection alter the outcome of TKA after tibial plateau fracture? *Clinical Orthopaedics & Related Research* 467(7):1793-9.

Del Pozo JL, Patel R. 2009. Infection associated with prosthetic joints. *New England Journal of Medicine* 361(8):787-94.

Spine

Kallmes DF, Comstock BA, Heagerty PJ, Turner JA, Wilson DJ, Diamond TH, Edwards R, Gray LA, Stout L, Owen S, Hollingworth W, Ghdoke B, Annesley-Williams DJ, Ralston SH, Jarvik JG. A randomized trial of vertebroplasty for osteoporotic spinal fractures. 2009. *New England Journal of Medicine* 361(6):569-79.

Tendon Regeneration

Omae H, Zhao C, Sun YL, An KN, Amadio PC. 2009. Multilayer tendon slices seeded with bone marrow stromal cells: a novel composite for tendon engineering. *Journal of Orthopaedic Research* 27(7):937-42.



To learn more about Mayo Clinic's ongoing orthopedic research, visit mayoresearch.mayo.edu/mayo/research/ortho/index.cfm

Advanced Foot Wound Management and Limb Salvage

Continued from page 3

effectiveness of the IPC device (Figure 2). It is now recognized nationally and internationally as a standard of care.

Low-Frequency Noncontact Ultrasound. This acoustical technique (MIST Therapy) delivers a very fine spray of saline mist to the wound (Figure 3). It painlessly cleans the wound and encourages growth of healthy tissues required for healing. All wound categories respond well to this therapy: neuropathic, ischemic or arterial, venous, infectious, small vessel, pressure, and multifactorial wounds.

Hyperbaric Oxygen Therapy (HBOT). Mayo Clinic's hyperbaric oxygen facility opened in 2007 and is one of the largest in use. It can accommodate 12 patients at once. HBOT involves the inhalation of oxygen at a partial pressure greater than 1 atmosphere. This is achieved by having patients comfortably seated in a pressure vessel while breathing oxygen, typically 100%, for 90 minutes daily, for a 40-day treatment cycle. By supersaturating the red blood cells, HBOT enhances the delivery of oxygen to granulation tissues to stimulate healing (Figure 4).

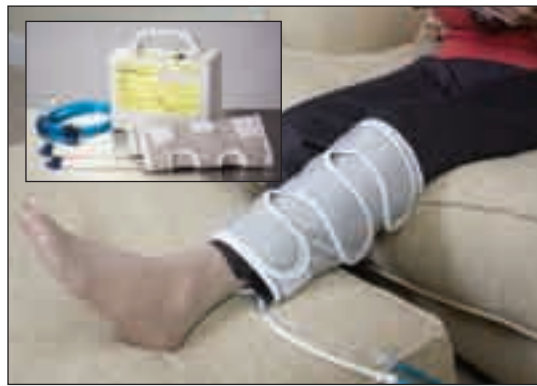

Figure 2. IPC device (inset). The calf cuff removes venous blood congestion to restore arterial flow and promote healing.



Figure 3. Adjunctive therapy consisting of a very fine saline mist spray that delivers ultrasound to the wound. The acoustical energy mechanically kills bacteria, thus cleaning the wound so healing can proceed.



Figure 4. Hyperbaric oxygen chamber. By supersaturating the red blood cells, this treatment enhances the delivery of oxygen to compromised tissues to stimulate healing.

Pediatric Anterior Cruciate Ligament Reconstruction: Options for Success in Skeletally Immature Patients

Tears to the anterior cruciate ligament (ACL) in skeletally immature patients are increasingly common, yet surgical management of young patients with wide open physes remains controversial. Concerns about surgical management of pediatric

ACL patients center on the use of traditional reconstruction techniques developed for adult patients. In skeletally immature patients, these techniques may cause leg-length discrepancy and angular malalignment due to violating the physes.



Amy L. McIntosh, MD

“For years, the accepted practice was to delay ACL reconstruction until the patient’s skeleton matured and to advise patients to modify their activities while waiting for their growth plates to close,” explains Mayo Clinic pediatric orthopedic surgeon Amy L. McIntosh, MD.

But the evidence suggests that advising an athletic child or teenager not to run, jump, cut, or pivot for months—or years, given that Dr McIntosh has seen ACL tears in an 8-year-old—is not effective. “Even with a brace, active children tend to put their knees in a position of recurrent instability,” Dr McIntosh says. “Then they risk damaging the underlying cartilage and meniscus. So at Mayo, we favor a phased approach to pediatric ACL reconstruction based on a patient’s skeletal development.”

Adds her colleague in general pediatrics, Philip R. Fischer, MD: “As more kids compete earlier in high-level sports, their knees are likely to experience stresses that have not occurred in this age group at this magnitude before. Treatment strategies are evolving to meet this need.”

A Phased Approach

The Mayo pediatric sports medicine surgery team uses a 3-phase approach based on skeletal development to evaluate reconstruction options. The first 2 phases affect the most skeletally immature patients. “Two groups of young patients cause special concern for orthopedic specialists, especially those who commonly treat adults,” Dr McIntosh says. “The data from pediatric sports medicine studies show satisfactory outcomes in these young patients” (Figure 1).

Prepubescent Patients. In children just entering

puberty who have considerable growth remaining, a physeal-sparing technique is typically indicated. The combined intra-articular and extra-articular reconstruction uses an autogenous iliotibial band graft that does not violate the physes.

Early Adolescent Patients. For patients who have reached puberty but who are still growing, a medial hamstring autograft ACL reconstruction through transphyseal tunnels yields satisfactory results. This approach reduces the risk of growth disturbance by placing a soft-tissue graft across the physes (Figure 2).

A therapeutic case series evaluated by Dr McIntosh and her Mayo colleagues and published in *Arthroscopy* in 2006 analyzed the results of transphyseal ACL reconstruction with medial hamstring autograft in 11 boys younger than 15 years and 5 girls younger than 14 years. With a mean clinical follow-up of 41.1 months, the approach yielded satisfactory clinical results: no new meniscal tears were identified and most patients returned to previous levels of activity. Importantly, physeal growth arrest did not occur.

Adolescent Patients Reaching Skeletal Maturity. In older adolescents who have complete tears and are near skeletal maturity, conventional ACL reconstruction used for adults is indicated. It involves interference screw fixation and either autogenous hamstring or autogenous central third patellar tendon and bone block.

Because more younger children are participating in high-demand sports, it is likely that the need for the phased treatment approach to pediatric ACL reconstruction will increase. “The future will generate more data to evaluate clinical outcomes and improve understanding of long-term graft performance. We hope these results will help us optimize not just treatment, but prevention of these injuries,” Dr McIntosh says.

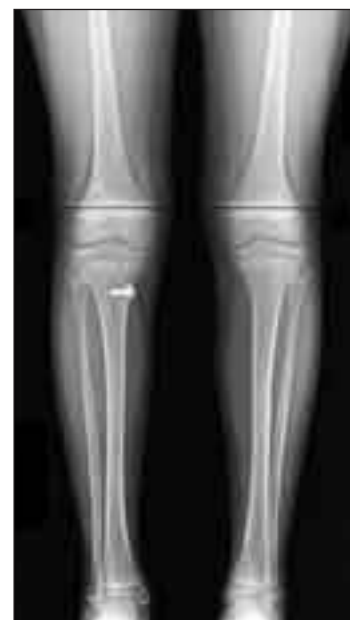

Figure 1. Postoperative scano-gram with hardware in place showing successful ACL reconstruction outcome: the operated leg has grown 2 cm since surgery; there has been no growth disturbance or angular malalignment.

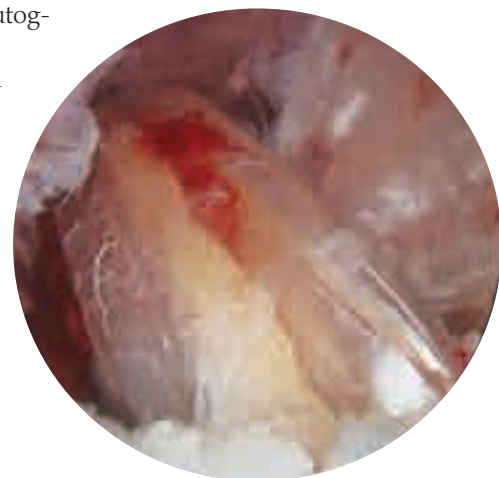


Figure 2. Intraoperative arthroscopic picture of the reconstructed ACL.

Mayo Clinic Orthopedic Update

Medical Editors

Daniel J. Berry, MD
Arlen D. Hanssen, MD
Michael J. Stuart, MD

Orthopedic Update is written for physicians and should be relied upon for medical education purposes only. It does not provide a complete overview of the topics covered and should not replace the independent judgment of a physician about the appropriateness or risks of a procedure for a given patient.

Contact Us

Referrals and Consultations

Arizona

866-629-6362

Florida

800-634-1417

Minnesota

Orthopedic Surgery
507-538-4101

All Other Referrals
and Consultations
800-533-1564

www.mayoclinic.org/medicalprofs

CME Opportunities

5th Mayo Clinic International Spine Symposium

January 31-February 4, 2010

Mauna Lani Resort, Big Island, Hawaii

Surgeons and nonoperative clinicians will interact with world-renowned faculty at Mauna Lani Resort, Big Island, Hawaii, during lively discussions of critical issues in spinal disorders and best-practices approaches for treating them. Enhanced with an audience response system to optimize learning, sessions focus on patient-centered care and the needs of physicians expanding their expertise. The symposium offers didactic lectures, panel discussions, case presentations, and debates over current issues. All are designed to be immediately relevant and applied to clinical practice.

Contact: 800-323-2688, cme@mayo.edu.

Shoulder Arthroscopy

April 30-May 1, 2010

Rochester, Minnesota

This advanced course for orthopedic surgeons treating disorders of the shoulder will integrate didactic sessions into cadaver-based laboratory experiences. Learning objectives include teaching the principles and techniques for management of rotator cuff tears, SLAP lesions, instability, and arthritis. In addition to hands-on learning, participants will engage in panel discussion and view live video demonstrations.

Contact: 800-323-2688, cme@mayo.edu.

Mayo Clinic Disorders of the Wrist

May 20-23, 2010

Rochester, Minnesota

Disorders of the Wrist, designed for orthopedic and plastic surgeons with a significant hand practice, covers the spectrum of disorders of the wrist and distal radioulnar joint. The format will be case-oriented, covering topics in bony and soft tissue trauma, degenerative disease, and inflammatory arthritis, to name a few. Videotaped surgery clips and cadaveric surgical dissection will be used to demonstrate complicated surgical procedures.

Preconference Workshop

An optional precourse skills training session will provide an opportunity to review normal hand and wrist anatomy. Participants will perform cadaveric dissection of the hand and wrist, view surgical demonstrations, and practice technique. This workshop is limited to 50 participants. A concurrent dry laboratory session will run a live video feed directly from the hands-on skills lab.

Contact: 800-323-2688, cme@mayo.edu.

To view all Mayo Clinic CME offerings visit www.mayo.edu/cme/



4500 San Pablo Road
Jacksonville, FL 32224

200 First Street SW
Rochester, MN 55905

13400 East Shea Boulevard
Scottsdale, AZ 85259

MC6247-0110

www.mayoclinic.org

©2008 Mayo Foundation for Medical Education and Research (MFMER).
All rights reserved. MAYO, MAYO CLINIC and the triple-shield Mayo logo
are trademarks and service marks of MFMER.