

## INSIDE THIS ISSUE

2 The Heart-Breast Scan: Screening for Breast Cancer in Patients Undergoing Myocardial Perfusion Imaging

4 Primary Aldosteronism: The Role of Adrenal Venous Sampling

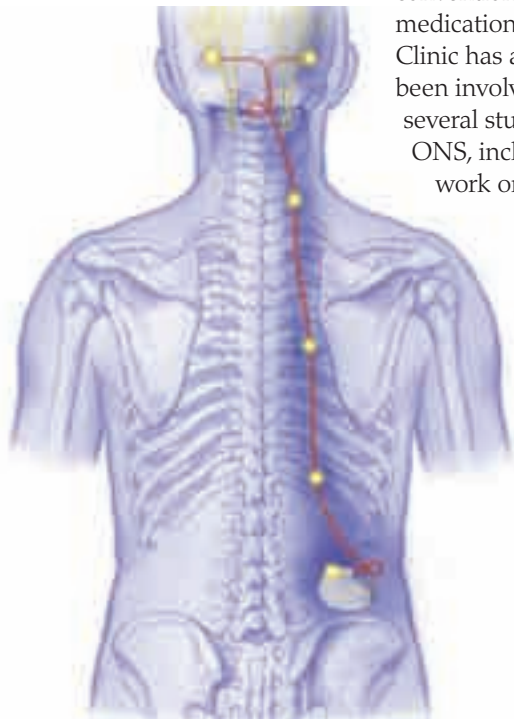
7 Sports Cardiology Clinic: Keeping Athletes Active

## Microstimulators Hold Promise for Some Medically Refractory Headaches

### The Challenge

More than 32 million Americans, 70% of whom are women, have migraines, and many of those affected progress to a chronic migraine condition, experiencing headaches more than 15 days per month. An estimated 40,000 people in the United States do not respond to existing treatments, and many may be candidates for alternative therapies.

Occipital nerve stimulation (ONS) for medically refractory headache pain has been available since the late 1990s. Offered at all 3 Mayo Clinic sites, it is most commonly used to treat migraine and cluster headaches that do not respond to conventional medications. Mayo Clinic has also been involved in several studies of ONS, including work on a



**Figure.** Traditional occipital nerve stimulation system.

### Points to Remember

- Although the mechanism is not entirely understood, peripheral nerve stimulation may influence deep brain centers that are responsible for pain modulation in headache.
- At Mayo Clinic, occipital nerve stimulation is most commonly used to treat migraine and cluster headaches that do not respond to conventional medications or psychological, behavioral, and alternative approaches to pain management.
- Microstimulators offer a less invasive way to treat refractory headaches while avoiding the risk of lead migration associated with occipital stimulators.
- These devices are still experimental and not yet approved by the US Food and Drug Administration.

microstimulator that is not yet commercially available.

In traditional ONS, a thin wire containing electrodes is implanted under the skin in the back of the head. The wire extends to an implantable, battery-driven impulse generator (Figure). Using a remote, handheld programmer, the patient controls the rate and intensity of the pulses. The pulses create paresthesias, often described by patients as light tingling or buzzing, in the area of the occipital nerve and the distal branches of the second and third cervical nerves. Although the mechanism is not entirely

understood, peripheral nerve stimulation may influence deep brain centers that are responsible for pain modulation and may gate or block pain signals from ascending from the trigeminal-cervical complex in the lower brainstem and upper cervical spinal cord.

### Advantages of Microstimulators

Lead migration has been one of the biggest frustrations experienced with the occipital stimulator. Microstimulators avoid that risk because both the electrodes and the impulse generator are contained within the stimulating device, which is about the size of a paperclip. Additionally, the microstimulator is less invasive and the surgery to implant it carries fewer risks. Traditional stimulators have long wires and require 3 incisions, while microstimulators require only 1 incision and have no wires.

### Patient Response to ONS

At Mayo Clinic, ONS is reserved for patients for whom all other treatments have failed. These

are people who have chronic daily headache and continuous, severe headaches for years who have tried everything from multiple medications to psychological, behavioral, and alternative approaches to pain management.

ONS complications can include infection and an increase in pain. Traditional ONS is first conducted on a trial basis to screen for increased pain. Because ONS takes time to work, patients may not experience improvement in the 5- to 7-day trial period. After the stimulation trial, the patient and physician decide if the response to the trial supports permanent implantation.

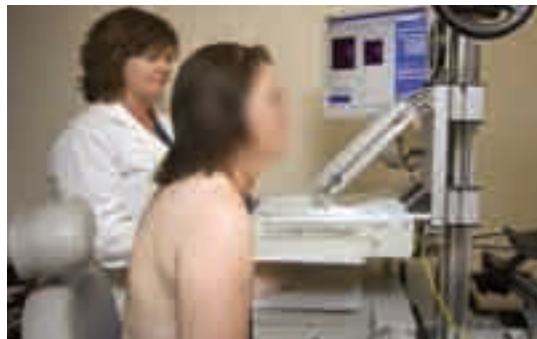Recently, Mayo Clinic researchers conducted the first test of microstimulators. In a small series of patients with medically refractory chronic cluster headache, 75% reported a positive response 3 months after implant. They have also found microstimulation to be effective in patients with hemicrania continua. These devices are still experimental and not yet approved by the US Food and Drug Administration.

## The Heart-Breast Scan

### Screening for Breast Cancer in Patients Undergoing Myocardial Perfusion Imaging

#### The Challenge

Several large-scale studies have demonstrated a clear benefit to mammographic screening for breast cancer, particularly in women older than 50 years. Despite its success, mammography is recognized as a less-than-perfect screening method. The limitations of mammography are particularly evident in women with dense breasts, where the sensitivity of mammography



**Figure 1.** A patient during MBI. The MBI system comprises dual semiconductor-based gamma cameras mounted on a modified mammography unit. The breast is lightly compressed between the 2 detectors to acquire views analogous to those obtained during mammography.

#### Points to Remember

- Currently under investigational study at Mayo Clinic, molecular breast imaging (MBI) is a new imaging technique with a high sensitivity for the detection of breast cancer.
- The Mayo Clinic Nuclear Cardiology Laboratory offers a combined heart-breast scan to any woman coming to the laboratory for a myocardial perfusion scan.
- A previous Mayo Clinic study found that in women at increased risk of breast cancer, MBI was 3 times more sensitive at early detection of breast cancer than screening mammography, while demonstrating better specificity.
- MBI can be combined with myocardial perfusion imaging to accurately assess a woman's risk for both conditions.

can be less than 50%. Increased breast density is a serious risk factor for breast cancer and is a major factor that greatly diminishes the value of mammography in the screening of younger women who have a high familial risk of breast cancer.

Results from several recent studies comparing mammography, ultrasonography, and magnetic resonance imaging (MRI) have consistently shown that both mammography and ultrasonography had a low sensitivity in women at increased risk, while MRI in the same patients had an increased sensitivity of between 75% and 100%. However, MRI has variable specificity and high cost (10 to 15 times that of mammography). Over the past 6 years, a new breast imaging technique called molecular breast imaging (MBI), which uses small, ultra-high-resolution gamma cameras, has been under development at Mayo Clinic in Rochester, Minnesota.

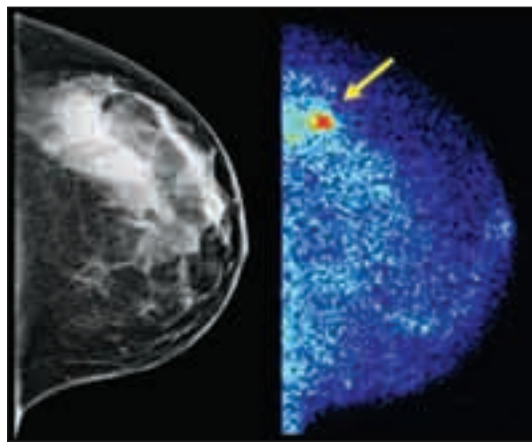
### Advantages of MBI

MBI uses small, ultra-high-resolution gamma cameras configured in a dual-head design in order to overcome limitations of older technologies. The 2 main technical problems associated with scintimammography that prevented the detection of small cancers were 1) the large cameras designed for whole-body imaging that did not allow close positioning to the breast and 2) the low resolution of the scintillating crystal technology. The compact design of the MBI system allows the breast to be positioned directly between 2 gamma cameras (Figure 1) in positions analogous to those used in mammography. Each gamma camera is also made up of small elements of a semiconductor called cadmium zinc telluride, which gives superior spatial and energy resolution compared with conventional technology and greatly improves image quality and the ability to detect small cancers (Figures 2 and 3).

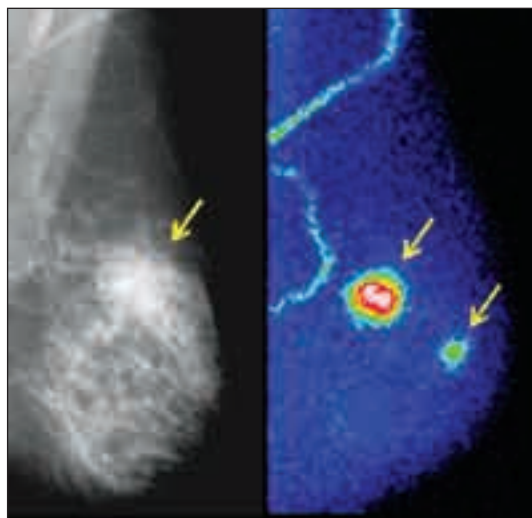
MBI has a high sensitivity of more than 93% for the detection of lesions measuring 5 to 10 mm. A recent large screening study at Mayo Clinic found that in women at increased risk of breast cancer, MBI was 3 times more sensitive at early detection of breast cancer than screening mammography, while demonstrating better specificity.

### Combined Heart-Breast Scan Study

The Mayo Clinic Nuclear Cardiology Laboratory offers a combined heart-breast scan to any woman coming to the laboratory for a clinically indicated myocardial perfusion scan (such as a technetium-sestamibi SPECT study). Interest in screening for breast cancer in women undergoing evaluation for coronary artery disease



**Figure 2.** The digital screening mammogram and screening MBI images from an asymptomatic patient with increased risk for breast cancer and extremely dense breasts on mammography. The digital mammogram (left) was interpreted as negative, but the MBI (right) detected a 13-mm invasive lobular cancer (arrow) that was occult on mammography due to breast density.



**Figure 3.** The mammogram and MBI images from a patient with a known 20-mm breast cancer detected by mammography (left, arrow). MBI (right) detected this cancer (upper arrow) and an additional 10-mm cancer (lower arrow) not detected on the mammogram. This patient had mildly dense breasts on mammography and no apparent risk factors for breast cancer, other than advanced age.

(CAD) has increased because there is a definite association between these 2 diseases. They share common risk factors, and some breast cancer treatments increase a woman's risk for developing CAD. Together, CAD and breast cancer combined represent a woman's greatest health risk over her lifetime. MPI can be combined with

*Continued on page 6*

# Primary Aldosteronism

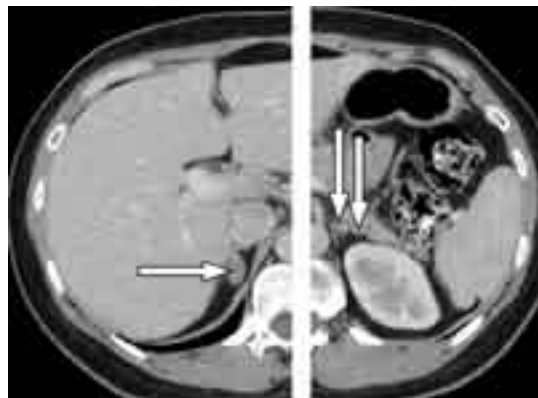## The Role of Adrenal Venous Sampling

### The Challenge

The triad of hypertension, hypokalemia, and an aldosterone-producing adenoma (APA) of the adrenal gland was first reported by Conn in 1955. Unilateral adrenalectomy in patients with an adrenal adenoma normalizes hypokalemia in all patients, normalizes blood pressure in at least a third of patients, and improves hypertension in nearly all patients. However, in patients with idiopathic hyperaldosteronism (IHA), a unilateral or bilateral adrenalectomy seldom corrects hypertension. Patients with IHA should be treated not surgically but medically with a mineralocorticoid receptor antagonist. Therefore, determining the subtype of PA (APA vs IHA) is critical in directing treatment.

### Distinguishing Between APA and IHA

Selective adrenal venous sampling (AVS) for aldosterone was first proposed in 1967 as a test to distinguish between APA and IHA. However, it is an invasive and difficult technique, and both adrenal veins must be sampled for meaningful comparison.



**Figure 1.** Adrenal CT scan of a 37-year-old woman with poorly controlled hypertension despite taking 3 antihypertensive drugs. The scan shows an 18-mm right adrenal nodule (arrow, left panel) and 2 left adrenal nodules of 7 mm and 4 mm (arrows, right panel). Adrenal venous sampling lateralized the aldosterone secretion to the right adrenal gland. A cortical adenoma (20×17×12 mm) was found at laparoscopic right adrenalectomy. At 18 months after surgery, the patient's postoperative plasma aldosterone concentration was low, and her blood pressure was normal without the aid of antihypertensive medications.

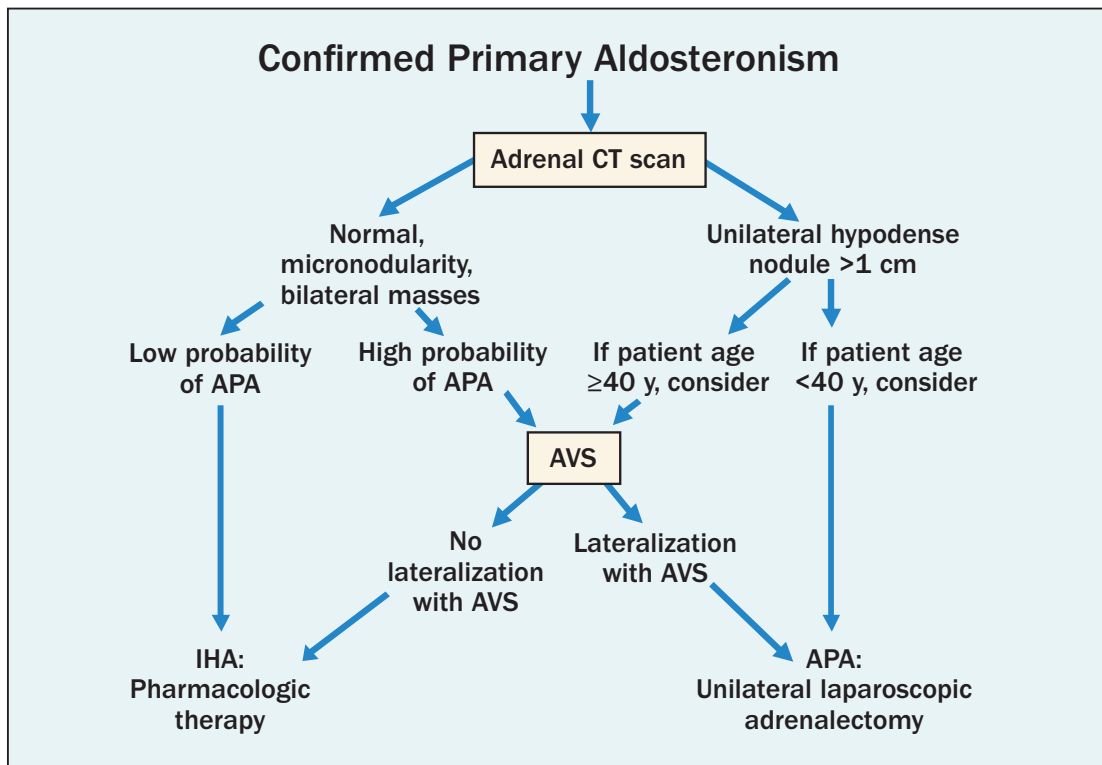
### Points to Remember

- Primary aldosteronism (PA) affects between 5% and 10% of all patients with hypertension.
- PA has more than one cause, and most patients with PA have bilateral idiopathic hyperaldosteronism (IHA).
- Because patients with IHA should be treated medically not surgically, distinguishing between aldosterone-producing adenoma (APA) and IHA is critical in directing treatment.
- For patients with PA who want to pursue the surgical treatment option, adrenal venous sampling (AVS) is an essential diagnostic step.

Computed tomography (CT) was initially thought to be a good test to distinguish among the subtypes of PA. However, because of the prevalence of nonfunctioning cortical adenomas, hormonal hyperfunction cannot be inferred simply from the presence of an adrenal nodule. Additionally, APAs that are 3 or 4 mm in diameter may escape detection on CT, and patients with a unilateral APA may have bilateral adrenal nodules on CT—one that is nonfunctional and one that is hypersecreting aldosterone (Figure 1).

An algorithmic approach to subtype evaluation of a patient with primary aldosteronism (Figure 2) helps determine when AVS is needed in patients with PA. Because adrenal incidentalomas are uncommon in young patients, when a solitary unilateral macronodule (>1 cm) and a normal contralateral adrenal are found on CT in a patient with PA, unilateral adrenalectomy is reasonable to consider. In addition, many patients prefer pharmacologic therapy and, therefore, do not require AVS. Using this approach, AVS is done in approximately 20% of patients with PA at Mayo Clinic in Rochester, Minnesota.

Patients with an APA have more severe

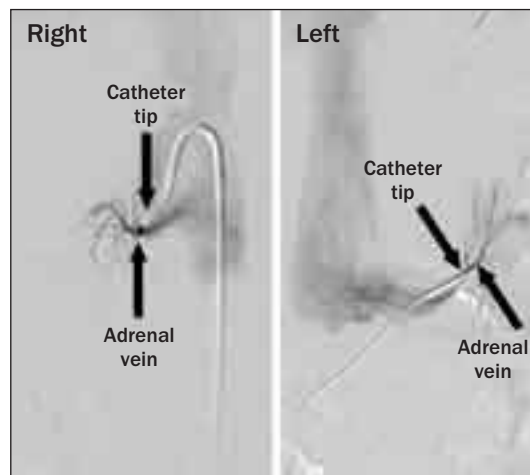


**Figure 2.** An algorithmic approach to subtype evaluation of a patient with primary aldosteronism. APA, aldosterone-producing adenoma; AVS, adrenal venous sampling; CT, computed tomographic; IHA, idiopathic hyperaldosteronism.

hypertension, more frequent hypokalemia, higher plasma (>25 ng/dL) and urinary (>30 µg/24 h) levels of aldosterone, and are younger than those with IHA. Patients with these findings are considered to have a high probability of APA (see Figure 2). However, these findings are not absolute predictors of unilateral (vs bilateral) adrenal disease. Therefore, AVS is an essential diagnostic step in most patients with PA, to distinguish between unilateral and bilateral adrenal aldosterone hypersecretion (see Figure 2).

During the procedure, the adrenal veins are sequentially catheterized through the percutaneous femoral vein approach under fluoroscopic guidance, and correct catheter tip location is confirmed with injection of a small amount of contrast medium (Figure 3). Blood is obtained by gentle aspiration from both adrenal veins. Successful catheterization may require an array of catheter configurations, either available from manufacturers or custom-made with steam shaping during the procedure to facilitate access to the adrenal veins. The placement of side holes very close to the catheter tip may enhance the progress of the blood draw.

At centers with experience with AVS, the



**Figure 3.** Images of adrenal venous sampling performed in the patient with primary aldosteronism whose CT scan is shown in Figure 1. Radiographs show catheters placed in the right and left adrenal veins.

complication rate is 2.5% or less. Complications can include symptomatic groin hematoma, adrenal hemorrhage, and dissection of an adrenal vein.

Aldosterone and cortisol concentrations are measured in the blood from all 3 sites (right adrenal vein, left adrenal vein, and

inferior vena cava) (Table). All blood samples should be assayed at 1:1, 1:10, and 1:50 dilutions—absolute values are mandatory. Accurate laboratory assays for cortisol and aldosterone are keys to successful interpretation of the AVS data.

Mayo Clinic has now performed AVS in more than 400 patients. For patients with PA who want to pursue the surgical treatment option, AVS is an essential diagnostic step.

**Table. Results of Bilateral Adrenal Venous Sampling (AVS) in the Patient With Primary Aldosteronism Who Had CT Scan (Figure 1) and AVS Radiographs (Figure 3)**

Vein	Aldosterone (A), ng/dL	Cortisol (C), µg/dL	A:C ratio	Aldosterone ratio*
Right adrenal vein	8,096	1,520	5.33	20.5
Left adrenal vein	225	870	0.26	
Inferior vena cava	41	22	1.86	

\*Right adrenal vein A:C ratio divided by left adrenal vein A:C ratio.

The cortisol concentrations from the adrenal veins and inferior vena cava are used to confirm successful catheterization; the ratio of adrenal vein cortisol to inferior vena cava cortisol is typically more than 10:1 when the protocol for continuous cosyntropin infusion is followed. Dividing the plasma aldosterone concentrations (PACs) of the right and left adrenal veins by the respective cortisol concentrations corrects for the dilutional effect of blood from the inferior phrenic vein flowing into the left adrenal vein; these quotients are termed *cortisol-corrected aldosterone ratios*. In patients with aldosterone-producing adenoma (APA), the mean cortisol-corrected aldosterone ratio (the ratio of APA-side PAC/cortisol concentration to normal adrenal PAC/cortisol concentration) is 18:1. A cutoff for the cortisol-corrected aldosterone ratio from high side to low side of more than 4:1 is used to indicate unilateral aldosterone excess. The lateralization ratio in this patient of 20.5:1 is consistent with a right adrenal APA.

## The Heart-Breast Scan: Screening for Breast Cancer in Patients Undergoing Myocardial Perfusion Imaging

*Continued from page 3*

myocardial perfusion imaging to accurately assess a woman's risk for both conditions.

The MBI scan is painless (only light breast compression is required) and can be performed during the waiting period between the stress study and cardiac imaging. As part of an ongoing research protocol, the MBI procedure is available at no additional charge to all female patients undergoing myocardial perfusion imaging in the Nuclear Cardiology Laboratory. Patients undergoing MBI must not have had breast biopsies, surgery, or radiation within the past year and must have a mammogram on record at Mayo within the past year, so that any findings on the MBI study can be correlated with a prior mammogram.

Patients are required to indicate on the study consent form their preference for

communicating any unexpected findings on the MBI study. If the patient elects to proceed with follow-up at Mayo, she will be seen at the Mayo Clinic Breast Center and will likely follow the standard of care that is already established at Mayo for the MBI screening program.

MBI was developed at Mayo Clinic in Rochester, and currently no other medical institution offers this combined heart-breast procedure. This test has the potential to enhance the clinical value of myocardial perfusion imaging for female patients by providing additional information on breast function that could only otherwise be obtained with expensive procedures such as contrast-enhanced MRI. In the future, this technique may also prove to have application in selected groups of women as a tool for initial breast cancer screening.

# Sports Cardiology Clinic

## *Keeping Athletes Active*

### The Challenge

Athletic performance often places extreme demands on the heart. Ensuring that the heart is healthy and fit enough for high-level training and competition is of paramount importance. Although relatively rare, sports-related symptoms and concerns do occur in adolescent and young adult athletes. And athletic training and competition now commonly extend into the fifth decade of life and beyond—when the possibility of cardiac disorders has greatly increased. Thus, thorough and thoughtful evaluation of the cardiovascular system of older athletes has become an important aspect of adult cardiology.

Mayo Clinic's Sports Cardiology Clinic in Rochester, Minnesota, has a team of physicians and allied health personnel who evaluate and treat cardiac symptoms with a priority of keeping athletes active in sports. Mayo's sports cardiologists have extensive experience diagnosing and treating cardiac conditions in athletes. Many team members also have personal athletic experience and understand the importance of sports participation in an individual's life. This means they will attempt to offer treatment to allow athletes to remain active in sports when possible. While the primary aim of the sports cardiology evaluation is to identify potentially serious cardiovascular disorders that could ultimately prove to be harmful if left unrecognized and untreated, guidelines for training and performance improvement are also provided.

### Program Components

The sports cardiology evaluation includes tests appropriate to an individual's situation, including

- Thorough review of medical history
- Review of athletic history
- Cardiovascular examination
- Evaluation of symptoms
- Electrocardiography
- Appropriate laboratory testing
- Cardiopulmonary exercise test
- Other diagnostic cardiac tests when indicated
- Training advice to improve athletic performance
- Optional sports nutrition consultation
- Optional sports medicine evaluation and

### Point to Remember

- The primary aim of the Sports Cardiology Clinic evaluation is to identify potentially serious cardiovascular disorders that could ultimately prove to be harmful if left unrecognized and untreated. Guidelines for training and performance improvement are also provided.

consultation for musculoskeletal and orthopedic concerns

- Physical therapy as indicated
- Referrals to other specialists if a health issue cannot be resolved by cardiologists

### Potential Patients

Patients who are appropriate for the Sports Cardiology Clinic include adult athletes who compete at any level, from recreational to high-level competition. Adolescent athletes at least 15 years of age may also be evaluated in the Sports Cardiology Clinic. Reasons for coming to the Sports Cardiology Clinic might include any of the following:

- Clearance to resume sports participation after cardiovascular surgery or a cardiac event
- Evaluation of symptoms like chest pain, palpitations, or shortness of breath that occur during training or competition
- Unexplained deterioration in performance
- Concern over family history of cardiovascular disease
- Athletic performance impaired by previously prescribed medical treatment
- Advice on controlling cardiovascular risk factors
- Comprehensive cardiovascular screening

### Appointments

Patients may be referred by their primary physicians, or they may make appointments on their own. To set up an initial evaluation with the Sports Cardiology Clinic, please call 507-284-3994, Monday through Friday, 8 AM to 5 PM Central time. For additional information, please see the Cardiovascular Health Clinic Web site at <http://www.mayoclinic.org/cardiovascularst/cardioheartclinic.html>.

## Mayo Clinic Clinical Update

**Medical Editor:**  
Scott C. Litin, MD

**Editorial Board:**  
Robert P. Shannon, MD  
Douglas M. Peterson, MD

*Clinical Update* is written for physicians and should be relied upon for medical education purposes only. It does not provide a complete overview of the topics covered and should not replace the independent judgment of a physician about the appropriateness or risks of a procedure for a given patient.

## Contact Us

Referrals and Consultations

### Arizona

866-629-6362

### Florida

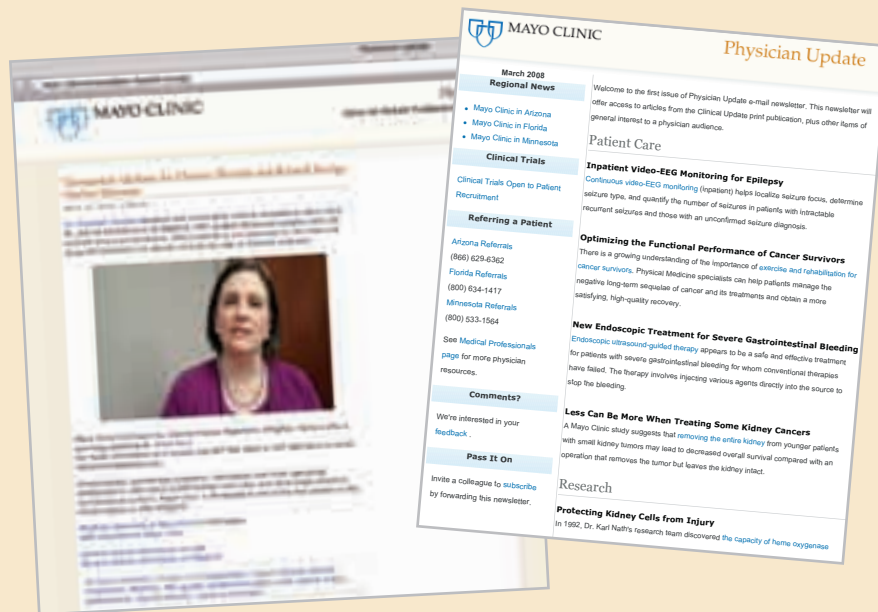
800-634-1417

### Minnesota

800-533-1564

[www.mayoclinic.org/medicalprofs](http://www.mayoclinic.org/medicalprofs)

## Physician Update



## Mayo Clinic has online options for medical professionals

An e-mail newsletter and a physician video blog. Visit [www.mayoclinic.org/medicalprofs](http://www.mayoclinic.org/medicalprofs) for more details.



4500 San Pablo Road  
Jacksonville, FL 32224

200 First Street SW  
Rochester, MN 55905

13400 East Shea Boulevard  
Scottsdale, AZ 85259

[www.mayoclinic.org](http://www.mayoclinic.org)

©2010 Mayo Foundation for Medical Education and Research (MFMER).  
All rights reserved. MAYO, MAYO CLINIC and the triple-shield Mayo logo  
are trademarks and service marks of MFMER.